The New England
Journal of Medicine

Copyright, 1955, by the Massachusetts Medical Society

Volume 252 JUNE 16, 1955 Number 24

GENERALIZED GASTROINTESTINAL POLYPOSIS*

An Unusual Syndrome of Polyposis, Pigmentation, Alopecia and Onychotrophia

LEONARD W. CRONKHITE, JR., M.D.,† AND WILMA JEANNE CANADA, M.D.‡

BOSTON

TWO cases are reported below in which the presenting complaints were disturbances in gastrointestinal function, pigmentation of the skin, alopecia and atrophy of the fingernails and toenails. In each case the underlying pathologic process seemed to be generalized gastrointestinal polyposis in which virtually the entire gastrointestinal mucosa was replaced by polypoid lesions. These cases are of interest in that they probably differ in nature from other syndromes that relate polyposis to pigmentation of the skin.

CASE REPORTS

CASE 1. E.S. (B.M. 733228), a 42-year-old single female bookkeeper, was first seen in March, 1951, because of nausea, vomiting and diarrhea of 2 months' duration. She was referred to the hospital by Dr. Earle Green, of Rockport, Massachusetts. Except for the usual childhood diseases she had been quite well throughout her life until 2 months before admission, when she experienced steady pain in the lower abdomen followed by nausea, vomiting and diarrhea. Six weeks later her scalp hair began to fall out, and she lost eyebrow and axillary hair. Still later a diffuse brownish pigmentation appeared over her face, neck and hands. There was no family history of gastrointestinal disease or skin pigmentation.

Physical examination revealed a well developed woman with striking pigmentary changes in the skin. The backs of the hands and fingers were deeply colored with a diffuse brown pigment, as were most of the body folds. The face and neck were streaked with brown, with ill defined brown patches on the perioral and buccal areas. In the retina were streaks of tan pigment. The scalp hair was scant. Pubic, axillary and facial hair was almost totally absent. The remainder of the physical examination was normal.

Laboratory studies showed an anemia (hemoglobin, 9.8 gm. per 100 cc.) and a white-cell count of 8800, with a normal differential; the hematocrit was 31 per cent. The eosinophil count was 360 per cubic millimeter initially, but dropped to 97 per cubic millimeter three hours after 25 mg. of ACTH. A stool specimen was negative for occult blood. The basal metabolic rate was +2 per cent. Serum electrolytes were normal, as was a glucose tolerance test. There was no free acid in the stomach. The serum cholesterol was 172 mg. per 100 cc. Urinary 17-ketosteroids were 5.1 mg. per 24 hours (normal).

X-ray studies of the stomach, duodenum and small and large bowel were striking. Examination of the upper gastrointestinal tract demonstrated multiple, large, fixed, polypoid filling defects in the stomach and duodenum (Fig. 1 and 2). The distal third of the stomach was less flexible than normal. Serial films of the small intestine showed coarsening of the mucosal pattern throughout, more marked in the jejunum, with scattered small, rounded filling defects. A barium-enema study demonstrated that the mucosa of the entire colon was covered with small, sessile, polypoid filling defects (Fig. 3), the largest measuring about 1 cm. in diameter. None of the colonic mucosa was free of these lesions.

A biopsy of one of the gastric lesions was obtained and reported as consistent with a benign adenomatous polyp.

Because of the extensive nature of the gastrointestinal lesions the patient was discharged on symptomatic therapy and dietary supplements. She continued to lose weight and to suffer from abdominal pain and diarrhea. Her hair continued to fall, and the skin pigmentation became more marked. There was gradual accumulation of edema. The fingernails and toenails became atrophic. She died at another hospital 8 months after the onset of symptoms.

At post-mortem examination§ the changes in the scalp and body hair, the atrophy of the fingernails and toenails and the pigmentary changes in the skin were noted as described above. Pitting edema extended from the feet to a point slightly above the costal margin. Over the hips were coalescent areas of epidermal bullae. Xanthelasma palpebrarum was present bilaterally. The tongue was atrophic and brown in surface color. The tip of the right index finger was black and gangrenous. There were small accumulations of fluid in the peritoneal, pleural and pericardial cavities. Examination of the lungs, heart, spleen, pancreas, kidneys and reproductive organs was unremarkable. The liver weighed 1818 gm. and felt greasy on cut surface. The gall bladder and biliary system were normal.

The gastrointestinal tract was opened throughout its entire length. The esophagus was normal. The stomach and duodenum disclosed a large number of pinkish polypoid masses, which obscured the entire mucosal architecture. Some of these masses were fixed to the underlying musculature. Most of the jejunum was uninvolved. The ileum showed large numbers of darker-colored polyps, some of which were more sessile than those found in the stomach. The large bowel was lined with polyps throughout its entire length. These were smaller and of a lighter color than those in the ileum. There were polyps in the rectum. No gross evidence of neoplasm existed anywhere in the gastrointestinal tract.

Gross examination of the adrenal and pituitary glands, bone marrow, aorta and brain was negative.

Microscopical examination of the tissues revealed a diffuse bronchopneumonia in the lungs, extensive fatty metamorphosis of the liver and normal adrenal glands. The lesions in the gastrointestinal tract were consistent with simple adenomatous polyps without evidence of malignant change.

*From the departments of Medicine and Radiology, Massachusetts General Hospital.

†Assistant in medicine, Harvard Medical School; clinical assistant in medicine, Massachusetts General Hospital; trainee, National Institute of Arthritis and Metabolic Diseases.

‡Associate radiologist, St. Luke's Hospital, New Bedford, Massachusetts; formerly, resident in radiology, Massachusetts General Hospital.

§Performed by Dr. M. L. Snell, of the Salem (Massachusetts) Hospital.

CASE 2. T.H. (M.G.H. 466683), a 75-year-old widow, entered the hospital with a chief complaint of diarrhea of 10 months' duration.

Twenty years previously she was seen at another hospital because of anemia and leukopenia. A diagnosis of pernicious anemia was made, and she was started on liver first by mouth and later by injection. This treatment was continued for the next 19 years, when it was stopped at the time the symptoms leading to the final hospital admission

FIGURE 1. *Roentgenogram in Case 1, Showing a Large Polypoid Filling Defect in the Fundus and Similar Smaller Defects in the Body of the Stomach.*

The visualized loops of small intestine show many scattered, rounded filling defects and generalized coarsening of the mucosal pattern.

appeared. The initial response to liver therapy was a remission of both the anemia and the leukopenia. Nine years before admission multiple brownish lesions appeared on the skin that were said to come and go. Ten months before admission she noted the onset of episodic crampy abdominal pain accompanied by watery, foul-smelling stools and associated at times with blood and mucus. Shortly thereafter she stopped receiving liver injections. Four months later there was sudden loss of scalp hair over a 3-day period, leaving her bald. At the time the fingernails and toenails turned black and fell off. There was a return of brown pigmentation of the skin, especially over the left forearm and hand, with interspersed areas of vitiligo. She entered the hospital because of progressive weakness, edema of the legs, numbness and tingling of the extremities, weight loss and severe, painful diarrhea.

There was no family history of skin pigmentation.

Physical examination revealed a cachectic, elderly woman whose scalp was covered by a few white hairs 1 cm. long. The fingernails and toenails were absent, but at the bases there appeared to be slight regeneration. There was a diffuse brown pigmentation over the arms and hands, with numerous areas of vitiligo. The lower extremities showed pitting edema to the knees. Chvostek's sign was positive. The remainder of the physical examination was unremarkable for her age.

Because of the striking similarity to Case 1 — that is, the alopecia, onychotrophia, skin pigmentation and gastrointestinal symptoms — a clinical diagnosis of generalized gastrointestinal polyposis was made and subsequently borne out by x-ray examination.

X-ray study of the chest revealed enlargement of the left ventricle, bilateral small pleural effusions and multiple fractured ribs, with a severe degree of demineralization of the visualized bones. A barium-enema examination showed slow filling, followed by incomplete evacuation. Both the conventional examination and a subsequent air-contrast study (Fig. 6 and 7), using colloidally stabilized barium sulfate, demonstrated the same type of polypoid filling defects as in the previous case (Fig. 3). Two examinations of the upper gastrointestinal tract, including study of the small bowel (Fig. 5), demonstrated many large confluent polypoid filling defects within the stomach mostly arising from the midportion of the greater curvature but with involvement of the entire gastric mucosa by smaller lesions (Fig. 4). The duodenal cap and proximal portion of the duodenal loop contained similar filling defects. Distal to the duodenal loop polyps were not demonstrated with certainty, though on both examinations there were scattered, small, rounded radiolucent areas within the barium column that were suspect. There was slight "puddling" of barium within loops of small bowel, but motility was normal. Attempts at a small-bowel enema were unsuccessful owing to the extreme inanition of the patient and the attending discomfort.

A number of laboratory examinations carried out are summarized briefly. The hemoglobin was 13.5 gm. per 100 cc., and the white-cell count 8400, with a normal differ-

FIGURE 2. *Roentgenogram in Case 1.*

A large polypoid mass fills the antrum of the stomach, and a separate large defect is visible in the duodenal cap.

ential. The eosinophil count was 100 per cubic millimeter, and the hematocrit 35 per cent; urinalysis was negative, as were a Sulkowitz test for urinary calcium and a stool examination for occult blood. The serum sodium was 139 milliequiv., the potassium 2.0 milliequiv., and the chloride 101 milliequiv. per liter; the calcium was 4.8 mg., the phosphorus 1.2 mg., and the alkaline phosphatase 4.4 units per 100 cc. The prothrombin time was 13 seconds (normal, 14 seconds). The total protein was 3.3 gm. per 100 cc., with an albumin of 1.1 and a globulin of 2.2 gm. per 100 cc. (albumin-globulin ratio of 0.5). Vitamin A was 0.3 units (normal 0.4 - 1.0 units) and carotenes 1.3 units per cubic centimeter (normal, 1.0 - 3.0 units). Vitamin A and glu-

cose tolerance tests orally resulted in flat curves. An electrocardiogram was normal except for frequent premature beats of atrial origin.

A biopsy taken from one of the polyps in the lower sigmoid was reported as showing a benign adenomatous polyp.

The patient was placed on a 2500-calorie, high-protein, low-sodium diet with a number of oral and parenteral supplements: potassium chloride, 2.7 gm., calcium lactate, 2.7 gm., and vitamin D, 100,000 units per day. In addition she was given quinidine sulfate, 0.3 gm. 4 times a day, tincture of opium, 10 drops 4 times a day, and cortisone, 50 mg. twice a day. While in the hospital she received intravenous fat and amino acids for 2 weeks. The net result of this treatment was eventual good symptomatic control of the abdominal pain and diarrhea, a small gain in weight and a return of the serum calcium and potassium to normal. She was followed at home for 6 months, and during this time was ambulatory and comfortable. At the end of this period she became more and more anemic despite the addition of vitamin B_{12} to the program. She gradually became disoriented, and congestive heart failure developed. She refused transfusion or hospitalization and died approximately 7 months after the final admission. Autopsy was not performed.

Discussion

From the many reported cases of polyposis in the literature, two quite distinct clinical entities have come to be generally accepted. The first of these, recognized originally by Cripps in 1882, has been

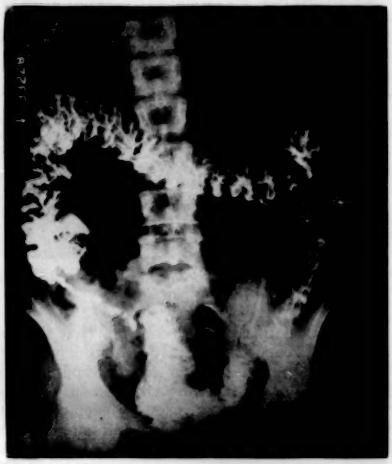

Figure 3. *Film Taken after Evacuation in Case 1, Showing Replacement of the Normal Mucosal Pattern by Varying-Sized, Separate and Confluent, Rounded Filling Defects. No normal mucosa is visible.*

called "polypoid adenomatosis of the colon." This condition is familial in nature, and the lesions are usually most evident in the large bowel. The polyps appear during adolescence and increase rapidly in numbers during the second and third decades. A second condition, reviewed thoroughly in 1949 by Jeghers et al. and known in this country as the "Peutz–Jeghers syndrome," combines intestinal polyposis with melanin spots of the oral mucosa, lips and digits. This, too, seems to be a familial disease though here the lesions are more prominent in the small

Figure 4. *Roentgenogram in Case 2. The distal portion of the stomach and the large duodenal bulb are filled with polypoid masses.*

bowel. Clinical manifestations of the disease occur early in life, usually during adolescence.

Cases falling into these two groups account for only a small proportion of the total number reported. Of the remainder, there is a great variation in clinical description, but all have in common the finding of one or more adenomatous polyps somewhere in the gastrointestinal tract. At one extreme is the single asymptomatic polyp located in any segment of the digestive tract, and at the other are cases in which virtually the entire gastrointestinal mucosa is replaced by masses of polypoid tissue. Whether these two extremes represent a difference in severity of the same disease process is still open to question. Thus, on the basis of present concepts, it is impossible to classify gastrointestinal polyposis in more than a superficial fashion: familial (polypoid adenomatosis of the colon and Peutz–Jeghers syndrome) and nonfamilial (single adenomatous polyps, multiple adenomatous polyps and generalized gastrointestinal polyposis).

By anatomic definition the 2 cases reported above fall into the last of these classifications. Similar cases in the medical literature are rare but have been reported occasionally.

Clinical Course

Several unusual features in the clinical courses of these 2 patients present themselves. In Case 1 the patient had apparently been well all her life until the age of forty-two when the first gastrointestinal symptoms developed. Within eight months the disease had progressed to the point that she literally died of starvation. Of interest is the fact that skin pigmentation and loss of hair began early in the course of the illness and were manifest while absorption tests were still normal. In contrast the patient in Case 2 complained of gastrointestinal symptoms and skin changes for many years, though she lived an active life until the age of seventy-five. At that time final symptomatology developed, and within eighteen months she too died of starvation.

FIGURE 5. *X-Ray Film in Case 2. Arrows indicate suspected polyps in the small intestine.*

FIGURE 6. *Conventional Postevacuation Film in Case 2. Arrows indicate some of the polypoid defects that replace the entire mucosal surface.*

Roentgenographic Findings

The x-ray findings in these cases were like those of any other case of multiple mucosal polyps of the gastrointestinal tract. The lesions are recognized as radiolucent, rounded or lobulated, fixed or movable, filling defects in the barium column, and may be pedunculated or sessile. Although a peduncle is often seen with single polyps it is less commonly encountered in diffuse polyposis, in which the barium shadow shows a characteristic coarse mottling. The lesions in the stomach, duodenum and colon are easily seen. The air-contrast enema, using colloidal barium sulfate (Fig. 7), demonstrates the colonic lesions to advantage. Polyps in the small intestine are usually more difficult to demonstrate. They were seen in Case 1 and subsequently found in large numbers at post-mortem examination. In Case 2 their presence was highly probable, as shown in the illustrations, but verification by post-mortem examination was not possible. The most striking roentgenologic feature in both cases was the extremely large number of polyps demonstrated.

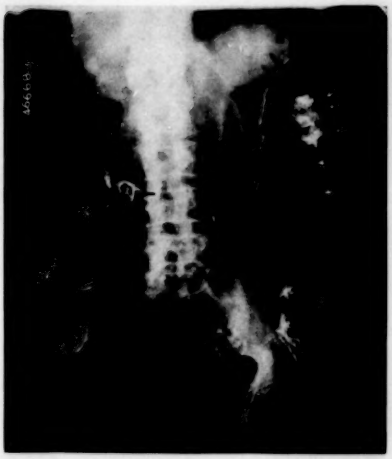

FIGURE 7. *Postevacuation Film in Case 2, Colloidally Stabilized Barium Sulfate and Air Contrast Being Used.*

Deficiency State

The most frequent causes of death in polypoid disease of the digestive tract are bleeding, malignant degeneration and intestinal obstruction. If no one of these catastrophic events occurs it is reasonable to assume that the disease will progress until gastrointestinal absorption or motility or both are so altered that general nutrition is impossible. Similar situations prevail in a number of other generalized diseases of the digestive tract, and a well recognized clinical pattern of multiple deficiencies results. The unusual feature of the 2 cases reported above is the striking prominence of changes in the hair, skin and nails.

Ectodermal Changes

The integrity of such ectodermal structures as hair, skin and nails is dependent on a variety of factors. A primary deficiency of substances such as vitamin A, riboflavin, pyridoxin, nicotinic acid and ascorbic acid is known to result in clinically evident change in these organs from the standpoint both of structure and of pigmentation. Many of the endocrinopathies, especially those affecting the adrenal and thyroid glands, are reflected in the integument by widespread change in hair, nails and skin pigment. Still other changes result from hereditary considerations or from a variety of systemic pathologic processes. Because of the limitations in clinical observation and in histologic technic it is often difficult to assign a specific etiology to an observed change in one of these structures. Thus, in Cases 1 and 2 of this paper, the exact nature of the deficiency is not clear though it seems reasonable to relate the altered absorption from the digestive tract to the ectodermal changes observed.

In severe cases of sprue, ulcerative colitis, regional enteritis and the like an analogous secondary deficiency state is common. Thinning of the hair, brittleness and atrophy of the nails, vitiligo and skin pigmentation have all been reported though not usually as primary clinical manifestations of the disease. One might suspect that the absorptive potential of mucosa altered by sprue is not the same as that of mucosa altered by the presence of adenomatous polyps. The difference in absorptive capacity, as well as the extensive distribution of the lesions, could account for qualitative as well as quantitative differences in the clinical picture.

Summary

Two cases of generalized gastrointestinal polyposis are presented in which alopecia, skin pigmentation and onychotrophia were prominent clinical features. It is suggested that these ectodermal changes are part of a generalized deficiency state and that their clinical prominence may be related to the extensive distribution of the lesions in all segments of the digestive tract. The relation of these cases to other types of polypoid disease is indicated.

We are indebted to Dr. D. A. Nickerson, of the Department of Pathology at the Salem (Massachusetts) Hospital, for allowing inclusion of the post-mortem findings in Case 1.

Bibliography

Abrams, H. L., Carnes, W. H., and Eaton, J. Alimentary tract in disseminated scleroderma with emphasis on small bowel. *Arch. Int. Med.* **94**:61-81, 1954.

Case Records of The Massachusetts General Hospital (Case 21061). *New Eng. J. Med.* **212**:263-267, 1935.

Dean, W. B., Spies, T. D., and Blankenhorn, M. A. Secondary pellagra. *Medicine* **23**:1-77, 1944.

Dukes, C. E. Familial intestinal polyposis. *Ann. Roy. Coll. Surgeons England* **10**:293-304, 1952.

Frazier, C. N., and Hu, C. K. Cutaneous lesions associated with deficiency in vitamin A in man. *Arch. Int. Med.* **48**:507, 1931.

Griesmer, R. D., Frazier, C. N., and Blank, I. H. Nutritional influences on physiology of skin: observations on metabolism of vitamin A. *Medicine* **32**:293-321, 1953.

Hills, O. W., Liebert, E., Steinberg, D. L., and Horwitt, M. K. Clinical aspects of dietary depletion of riboflavin. *Arch. Int. Med.* **87**: 682-693, 1951.

Jeghers, H. Pigmentation of skin. *New Eng. J. Med.* **231**:88-100, 122-136 and 181-189, 1944.

Jeghers, H., McKusick, V. A., and Katz, K. H. Generalized intestinal polyposis and melanin spots of oral mucosa, lips and digits. *New Eng. J. Med.* **241**:993-1005 and 1031-1036, 1949.

Lockhart-Mummery, J. P. Causation and treatment of multiple adenomatosis of colon. *Ann. Surg.* **99**:178-184, 1934.

Moore, S. W. Polyps of large intestine. *Am. J. Surg.* **82**:390-395, 1951.

Ralli, E. P., and Sherry, S. Adult scurvy and metabolism of vitamin C. *Medicine* **20**:251-340, 1941.

Ravdin, I. S., and Ravdin, R. Adenomatous polyposis of colon. *S. Clin. North America* **31**:1745-1751, 1951.

Ravitch, M. M. Polypoid adenomatosis of entire gastrointestinal tract. *Ann. Surg.* **128**:283-298, 1948.

Spira, L. Riehl's melanosis and adrenal glands. *Arch. Int. Med.* **86**: 682-690, 1950.

Stefanini, M. Clinical features and pathogenesis of tropical sprue. *Medicine* **27**:379-427, 1948.

Sulzberger, M. B., and Lazar, M. P. Hypervitaminosis A. *J.A.M.A.* **146**:788-793, 1951.

Tempest, M. N. Diffuse polyposis of stomach. *Brit. J. Surg.* **38**:525, 1951.

Wolff, H. H. Familial intestinal polyposis with pigmentation of lips, oral mucosa, face, and digits. *Lancet* **2**:446-448, 1952.

CARDIOVASCULAR DISTURBANCES AND THEIR MANAGEMENT IN MODIFIED ELECTROTHERAPY FOR PSYCHIATRIC ILLNESS

WILLIAM HALL LEWIS, JR., M.D.,* D. JEANNE RICHARDSON, M.D.,† AND LAWRENCE H. GAHAGAN, M.D., PH.D.‡

NEW YORK CITY

CARDIOVASCULAR strain produced in psychiatric electrotherapy (electroconvulsive therapy) is largely manifested by marked paroxysmal rises in the arterial and venous pressures and by disturbances in the initiation and conduction of the cardiac impulse.[1-10] These disturbances, which may result in death, have tended to limit the use of this treatment in elderly and frail patients, and in those with cardiovascular disease.

There is substantial evidence that the leading cause of death in electrotherapy is failure in the cardiovascular system and also that the risk of death is greatly increased in older patients. This has been best presented in the authoritative report of Maclay[10]; 62 deaths in electroconvulsive therapy (modified and unmodified) are known to have occurred in hospital patients in England and Wales from 1947 to the middle of 1952 (Fig. 1 and 2). All but 6 of the deaths were in persons over thirty-five years, and more than half (56 per cent) were in persons over fifty-five years of age. Also, 41 of these 62 deaths were due to failure in the cardiovascular system, including 4 caused by intracranial vascular lesions and 3 by pulmonary emboli. (In addition, 5 deaths during this period occurred during the special method of electronarcosis; these are not included in the discussion.)

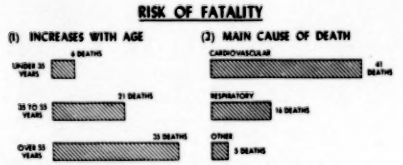

FIGURE 1. *Analysis of 62 Deaths in Psychiatric Electrotherapy Occurring in England and Wales, 1947 to July, 1952 (Based on Data of Maclay[10]).*

In unmodified psychiatric electrotherapy the main nonfatal complication is fracture, and the main fatal complication is cardiovascular failure.

Although there is no comparable American report, the experience in this country is undoubtedly similar since the same types of patients receive treatment by similar methods. Alexander,[11] in Boston, has pointed out that circulatory disturbances are the most important and dangerous complications of electrotherapy. He has classified cardiovascular accidents due to treatment under four headings: acute heart failure (myocardial failure or infarction, or both); vascular collapse; pulmonary edema; and disturbances of the heart rhythm. The frequency of treatment-induced cardiac arrhythmias in several representative studies is shown in Figure 3.

Although there are, we believe, no absolute contraindications to psychiatric electrotherapy, certain cardiovascular diseases — especially recent myocardial infarction, severe congestive heart failure, aortic aneurysm, complete heart block and paroxysmal ventricular tachycardia — would cause one to proceed with caution or, perhaps whenever possible, to postpone such therapy until the cardiovascular status has improved. However, electrotherapy should not be unduly withheld in mental patients with serious cardiovascular disease for three cogent reasons: the grim possibility of suicide is always present, especially in the depressed patient; the untreated mental illness imposes a burden on the circulatory system that may well exceed the risk imposed by treatment; through the use of modifying and adjunctive procedures the cardiovascular strain produced in treatment may in many cases be substantially lessened. The present investigation is largely directed toward the development of a procedure for treating patients who because of age or cardiovascular status would be regarded as poor risks. The method outlined requires the teamwork of the cardiologist, anesthetist and psychiatrist.

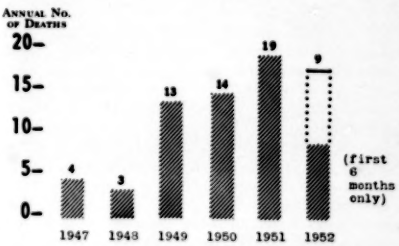

FIGURE 2. *Annual Hospital Deaths As a Result of Electroconvulsive Therapy in England and Wales, for the Five-and-a-Half-Year-Period Beginning in 1947 (Based on Data of Maclay[10]).*

*Consulting cardiologist, Doctors Hospital; assistant attending physician, Memorial Center for Cancer and Allied Diseases; consulting cardiologist, Rockland State Hospital, Orangeburg, New York.

†Clinical assistant professor of anesthesiology, New York University—Bellevue Medical Center; assistant attending anesthetist, Doctors and Bellevue hospitals.

‡Formerly, consultant in psychiatry, United States Public Health Service.

Method

Technic of Modified* Electrotherapy with Continuous Electrocardiography (Table 1)

The patient, fasted for three hours, is treated in his hospital room. Pretreatment sedation and other medications such as chlorpromazine, digitalis, quinidine and various hypotensive agents (for example, *Rauwolfia serpentina,* or reserpine) are given according to the requirements of the individual case.

Electrocardiography is begun shortly before each treatment and continued throughout treatment, including the recovery phase. The total time is usually fifteen to twenty minutes. During the brief period of electric stimulation the electrocardiogram is cut off or obliterated; for these few seconds the heart's rate and rhythm can then be detected through precordial auscultation. Arterial blood pressure is recorded at intervals of one or two minutes with the sphygmomanometer.

Rapid and short-acting intravenous barbiturate anesthesia, usually by means of 0.5 per cent thiamylal sodium by drip, is begun and continued until shortly before the application of the electric stimulus. The average dose of thiamylal was 400 mg., which is, however, substantially less when the patient is prepared with chlorpromazine. Other intravenous medications, as required, are given by means of puncture of the rubber tubing of the intravenous set; therefore, only one venepuncture per treatment is required. An additional advantage of this method is that a vein is always immediately available for emergency medication, which is especially desirable in case of vasomotor collapse. Occasionally, thiopental or pentobarbital sodium was used instead of thiamylal. All these rapidly acting barbiturate solutions are satisfactory and are effectively interchangeable.



FIGURE 3. *Frequency of Cardiac Arrhythmias in Psychiatric Electrotherapy As Reported in Representative Studies.*

Atropinization, which is usually indicated, is done preferably by the intravenous route, the drug being injected shortly before or after the intravenous barbiturate drip is begun. We recommend, whenever atropine sulfate is used, a dose of 1.2 to 2.4 mg. (1/50 to 1/25 grain); this is higher than the commonly recommended dose. Atropine has two important and beneficial effects in psychiatric electrotherapy: it prevents excessive vagal activity, and it prevents excessive secretions in the respiratory passages. A strong surge of vagal tone produced by the electric stimulation appears to be most intense about the time the convulsive response subsides; it is responsible for a profound slowing and sometimes a standstill of the heart. These disturbances in the initiation and conduction of the cardiac impulse have been well described elsewhere as "alarming" and have been regarded, probably correctly, as a cause of sudden and unexplained death in electrotherapy.[3,6]

*Modified with thiamylal, succinylcholine and oxygen.

TABLE 1. *Technic of Modified Psychiatric Electrotherapy with Continuous Electrocardiography.*

1.	PRETREATMENT AS REQUIRED. Intravenous atropinization is recommended to prevent excessive vagal activity and excessive secretion.
2.	CONTINUOUS ELECTROCARDIOGRAPHY. Started shortly before treatment; continued through recovery period.
3.	CONTINUOUS INTRAVENOUS BARBITURATE DRIP.
4.	SUCCINYLCHOLINE CHLORIDE. Administered intravenously as soon as patient loses consciousness.
5.	CONTROL OF RESPIRATION. 100 per cent oxygen.
6.	ELECTROSTIMULATION. Applied as soon as succinylcholine-induced fasciculations have subsided.

Succinylcholine chloride, in an average dose of 60 mg. with a range of 30 to 140 mg., is rapidly injected intravenously as soon as the patient has lost consciousness. A Guedel type of airway is inserted. Controlled respiration with 100 per cent oxygen by bag and mask is begun. This is continued until spontaneous respiration is re-established in the post-stimulus recovery period. The average period of apnea is five minutes, ranging from a low of one and a half to a high of seventeen and a half minutes.

Electric stimulation, with the use of the conventional or Cerletti–Bini technic, is applied as soon as the muscle twitching produced by succinylcholine has subsided. This indicates the time of onset of the maximal effect — that is, the maximal myoneural blockade or so-called "muscle relaxation" of succinylcholine; its short duration of action is one of several striking advantages of succinylcholine over the several other myoneural blocking agents that have been used in psychiatric electrotherapy. The fasciculations usually disappear within a minute of the injection of succinylcholine. If the dose is sufficient, the muscular response to the electric stimulus will be barely perceptible, or there may only be signs of autonomic excitation — for example, pilomotor response, dilatation of the pupils and a sudden and marked elevation in the arterial pressure (Fig. 4). The electric stimulus is ordinarily applied for two one-second intervals.

Results

At the time this report was submitted for publication we had given a total of 220 modified treatments

with continuous electrocardiography to 21 patients, 12 women and 9 men (Fig. 5). Their ages ranged from thirty-five to eighty-five years. Mostly they were poor risks; in several cases treatment had been refused or discontinued elsewhere because of complications or contraindications. Three patients had attempted suicide. Three (including 2 who had attempted suicide) had been severely injured in previous courses of unmodified treatment. Pathologic conditions found in this group included aortic aneurysm, valvular (rheumatic) heart disease, coronary-

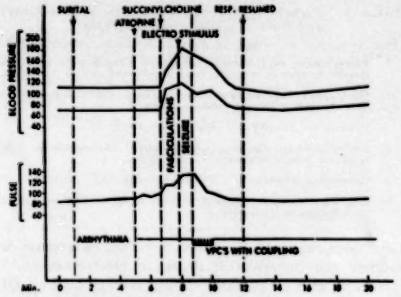

FIGURE 4. *Changes in Blood Pressure and Pulse and Arrhythmias in a Typical Case of Modified Psychiatric Electrotherapy.*

artery disease with old coronary thrombosis and healed myocardial infarction, myocardial insufficiency, hypertensive and arteriosclerotic heart disease, advanced osteoporosis, recent unhealed fractures, recent unhealed abdominal operation, infantile cerebral palsy with spinal deformity and the various debilities of old age.

In 103 (46.8 per cent) of the 220 treatments cardiac arrhythmias of various degrees of severity were noted. These disturbances were found in 16 of the 21 patients and ranged from mild (8 patients) to very severe (3 patients). The disturbances were rated as *mild* in 15 treatments, *moderate* in 52 treatments, *severe* in 28 treatments, and *very severe* in 8 treatments. The criteria for estimating the severity of the treatment-induced arrhythmias are shown in Figure 5.

The arrhythmias produced in treatment are conveniently divided into those of *vagal* and those of *extravagal origin*. Vagal arrhythmias are characterized by marked slowing and occasional standstill of the heart and are preventable by adequate atropinization as described.[9,11,14] Since a dose of 2.4 mg. of atropine sulfate by vein will completely block the cardiac portion of the vagus nerve and thereby prevent arrhythmias of vagal origin, any rhythm disturbances that then occur in treatment must be of extravagal origin.[12] In 117 treatments, involving 17 patients, full atropinization (2.4 mg.) was done before the electric stimulus was applied. In 60 (51.3 per cent) of these treatments, there were rhythm disturbances, necessarily classified as extravagal. This high rate of extravagal arrhythmias is not surprising when one considers the selection of patients, especially their cardiovascular status. In 3 patients, who received a total of 29 treatments, extravagal arrhythmias were produced in every treatment. All these patients had pre-existing cardiovascular disease or dysfunction, and they accounted for 6 of the 8 arrhythmias that were classified as very severe.

The most common extravagal arrhythmias were ventricular premature contractions. These might arise immediately after the electric stimulation or might be delayed for as long as several minutes. Usually, they arose within less than a minute of the application of the stimulus. These contractions could arise from one or more foci and were sometimes associated with an incipient breakdown of the basic cardiac rhythm. The arrhythmias were frequently bigeminal and occasionally trigeminal, lasting for as long as eighteen minutes after the electric stimulation. Sometimes, the extrasystoles ended abruptly; at other times they gradually washed out, with intervening periods of regular sinus rhythm. In every case the arrhythmias produced by a given treatment had

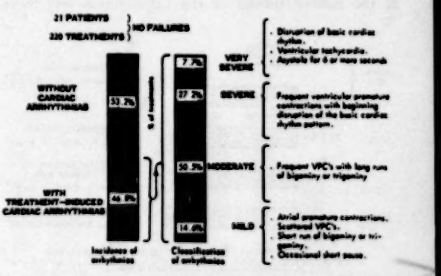

FIGURE 5. *Results of Modified Electrotherapy with Continuous Electrocardiography in Poor-Risk Patients. VPC=ventricular premature contractions.*

disappeared by the time of the next treatment, which was usually the following day. In addition to the ventricular premature beats there were rarer cases of atrial premature contractions, bundle-branch block and delayed intraventricular conduction with shortened PR intervals. Each patient tended to show a characteristic pattern of cardiovascular response in treatment, but this was not a definitely predictable reaction. Under identical methods of treatment a patient might one day show a marked arrhythmia with no disturbance of rhythm on the next; this, of course, complicates the evaluation of drugs to reduce treatment-induced arrhythmias.

Our experience with oral administration of quini-

dine in the alleviation of treatment-induced arrhythmias was inconclusive and requires further observations, especially with larger doses of the drug. The use of quinidine in electrotherapy has already been reported favorably by others.[9,11] In 1 of our patients the combined use of quinidine by mouth and atropine by intravenous injection was highly effective in preventing treatment-induced arrhythmias, although either drug alone was ineffective; this merely illustrates the complexity of the problem.

Our experience with chlorpromazine, based on its use during a total of 35 treatments in 6 patients, leads to the tentative opinion that it is effective as a rule in reducing or preventing treatment-induced arrhythmias. In only 1 case did this drug fail to have an ameliorative effect, and that failure occurred in a patient in whom the drug was effective in other treatments. The mode of action of chlorpromazine is not altogether clear, but it seems reasonable to assume that it can dampen the circulatory commotion produced in electrotherapy through central action.[13] This is indeed the main object of our study, and we are much encouraged by our preliminary findings with this remarkable drug.

It is well known that electrotherapy, modified and unmodified, characteristically causes a paroxysmal rise in arterial pressure (Fig. 4). Under the conditions of our investigation this elevation usually lasted for ten to thirty minutes. The important fact is that complete myoneural blockade does not prevent the paroxysmal rise in blood pressure. This is additional evidence that the main circulatory responses in electrotherapy are of central origin and are therefore

TABLE 2. *Purpose in Modifying Psychiatric Electrotherapy by Myoneural Blockade.*

1.	Cardiovascular strain can be detected & restorative measures immediately instituted.
2.	Work of heart reduced by elimination of convulsive movements.
3.	Hypoxia prevented throughout treatment (positive-pressure oxygen can be supplied at all times).
4.	Fractures & other traumatic complications prevented.
5.	Electrotherapy can be given despite pre-existing complications such as impaired cardiovascular function, unhealed fractures, advanced osteoporosis & recent surgical operations.

barely, if at all, affected directly by myoneural blockade. But there are undoubtedly indirect beneficial effects on the circulation — for example, hypoxia is entirely preventable when positive-pressure oxygen is supplied to the patient who is under a myoneural blockade (Table 2).

With the exception of 1 patient, a fifty-four-year-old woman without known or suspected heart disease, the changes in the electrocardiographic complexes produced in treatment were usually slight and transient. In this exceptional case T-wave inversion in Leads 1, 2, V_4, V_5 and aVL immediately followed treatment. These changes gradually disappeared after several weeks, when treatment was resumed without further incident.

There was usually no change in atrioventricular (PR interval) and intraventricular (QRS complex) conduction time during treatment, although there were a few cases of shortened PR interval associated with prolongation of QRS complex; this simulated the Wolff–Parkinson–White syndrome.

There was frequently a slight and temporary depression of the RS-T segment in several leads. The upright T wave was also sometimes slightly decreased in voltage in various leads; if the pretreatment voltage was small, the T wave might become flattened or even slightly inverted. This occurred more commonly in Lead 1 alone than in Leads 1, 2 and aVL together.

TABLE 3. *Advantages of Succinylcholine over Other Myoneural Blocking Agents in Psychiatric Electrotherapy.*

1.	Prompt & brief action.
2.	Dangerous side effects & cumulation absent.
3.	Predictable dose-response relation.
4.	Onset of maximal action readily detected.
5.	Greater acceptability to patient, who awakens sooner & is less confused.
6.	Generally decreased risk associated with over-all shortened period of respiratory depression.

Succinylcholine is by all means the most suitable myoneural blocking agent now available for the modification of psychiatric electrotherapy. We have already mentioned one of its advantages — that is, the ease and precision with which the onset of maximal effect can be detected. Others are its prompt and brief action, the lack of cumulation and of dangerous side effects, a predictable dose-response relation, its greater acceptability by the patient, who awakens earlier and less confused, and the generally decreased risk associated with the over-all shortened period of impaired respiration (Table 3). It should be pointed out, however, that succinylcholine is not always and altogether inert so far as the cardiovascular system is concerned. The onset of the fasciculations (depolarization phenomena) produced by succinylcholine is frequently associated with a sudden and marked rise in both systolic and diastolic pressure — that is, paroxysmal hypertension. In 1 of our patients there was usually, in addition to the sudden rise in blood pressure, a run of ventricular premature beats with coupling shortly after the injection of succinylcholine. A similar occurrence of ventricular extrasystoles has been described elsewhere.[13]

There was also 1 noteworthy case (that of a sixty-eight-year-old patient with an aortic aneurysm) in which the injection of 60 mg. of succinylcholine was followed by a vasomotor collapse, the blood pressure being unobtainable for six minutes. At the time of this peripheral vascular collapse the patient was under light thiamylal anesthesia and had also received an intravenous injection of 2.4 mg. of atro-

pine sulfate. The blood pressure was quickly restored to a normal level by the rapid intravenous injection of ephedrine sulfate (20 mg.), and the electric stimulation was then given without further difficulty. It is quite likely that the relation of the injection of succinylcholine to the vasomotor collapse was merely coincidental. This incident is largely of value to illustrate the desirability of having a vein always accessible for emergency medication.

Summary and Conclusions

Electrotherapy for psychiatric illness has usually been restricted in patients with cardiovascular disease. Cardiovascular strain has been the major source of death in treatment; this hazard is disproportionately increased in older patients.

A modified technic that aims at the amelioration of such a strain in treatment is described. This technic also avoids the traumatic complications of treatment.

Cardiac arrhythmias produced in treatment are defined. Such arrhythmias are conveniently divided into vagal and extravagal disturbances, according to their origin.

Arrhythmias of vagal origin can be prevented by adequate atropinization. Whereas those of extravagal origin cannot be uniformly prevented, quinidine and chlorpromazine appear to lessen their severity and in certain cases to prevent their occurrence. Chlorpromazine is especially promising in this respect.

References

1. Altschule, M. D., Sulzbach, W. M., and Tillotson, K. J. Effect of electrically induced convulsions on peripheral venous pressure in man. *Arch. Neurol. & Psychiat.* **58**:193-199, 1947.
2. *Idem.* Significance of changes in electrocardiogram after electrically induced convulsions in man. *Arch. Neurol. & Psychiat.* **58**: 716-720, 1947.
3. Bankhead, A. J., Torrens, J. K., and Harris, T. H. Anticipation and prevention of cardiac complications in E.C.T. *Am. J. Psychiat.* **106**:911-917, 1950.
4. Bellet, S., Kershbaum, A., and Furst, W. Electrocardiogram during electric shock treatment of mental disorders. *Am. J. M. Sc.* **201**:167-177, 1941.
5. Brown, M. L., Huston, P. E., Hines, H. M., and Brown, G. W. Cardiovascular changes associated with electroconvulsive therapy in man. *Arch. Neurol. & Psychiat.* **69**:601-608, 1953.
6. Hejtmancik, M. R., Bankhead, A. J., and Herrmann, G. R. Electrocardiographic changes following electroshock therapy in curarized patients. *Am. Heart J.* **37**:790-805, 1949.
7. Holmberg, G., et al. Circulatory conditions in electroshock therapy with and without a muscle relaxant. *Arch. Neurol. & Psychiat.* **72**:73-79, 1954.
8. Kline, E. M., and Fetterman, J. L. Electrocardiographic changes following electrically induced convulsions. *Am. Heart J.* **24**:665-670, 1942.
9. Nowill, W. K., Wilson, W., and Borders, R. Succinylcholine chloride in electroshock therapy. II. Cardiovascular reactions. *Arch. Neurol. & Psychiat.* **71**:189-197, 1954.
10. Maclay, W. S. Death in treatment. *Proc. Roy. Soc. Med.* **48**:13-20, 1955.
11. Alexander, L. *Treatment of Mental Disorder.* 507 pp. Philadelphia: Saunders, 1953.
12. Gold, H., Kwit, N. T., Otto, H., and Fox, T. J. On vagal and extravagal factors in cardiac slowing by digitalis in patients with auricular fibrillation. *J. Clin. Investigation* **18**:429-457, 1939.
13. Dundee, J. W. Review of chlorpromazine hydrochloride. *Brit. J. Anaesth.* **26**:357-379, 1954.
14. Gahagan, L. H. Cardiovascular responses in electroshock therapy. In *Cyclopedia of Medicine, Surgery and Specialties.* Edited by G. M. Piersol. Philadelphia: Davis, 1954. Review Service Volume. Pp. 253 and 254.
15. Martin, R. C., Nowill, W. K., and Stephen, C. R. Evaluation of succinylcholine. *Anesthesiology* **15**:179-187, 1954.

PATHOGENICITY OF STAPHYLOCOCCI*

A Comparison of Alpha-Hemolysin Production with the Coagulase Test and Clinical Observations of Virulence

George Gee Jackson, M.D.,† Harry F. Dowling, M.D.,‡ and Mark H. Lepper, M.D.†

With the Assistance of:

Winifred Rickert, B.S.,§ and Ethel Rosenthal, B.S.§

CHICAGO

THE bacterial species *Micrococcus pyogenes* var. *aureus (Staphylococcus aureus)* is often highly pathogenic for human beings, but the virulence of individual strains within the species varies considerably and except when a strain has been isolated from an obviously infected lesion its pathogenicity is always open to question. For this reason any test that can be correlated with pathogenicity in human patients is desirable. The production of coagulase is the test most widely used to indicate pathogenicity in vitro, and yet coagulase-positive staphylococci are commonly found in the absence of disease and, vice versa, coagulase-negative staphylococci occasionally cause infection. The present study was undertaken to correlate clinical pathogenicity with the production of alpha hemolysin by strains of staphylococci obtained from various sites in human beings under varying conditions of health and disease, and to make some observations regarding the reliability of the measurement of alpha hemolysin in vitro.

Alpha hemolysin is one of at least four hemolytic exotoxins produced by the species *M. pyogenes.*[1,2] The alpha hemolysin is active against rabbit and sheep erythrocytes at 37°C. and can be differentiated from beta hemolysin, which is a hot-cold substance that lyses sheep erythrocytes but is inactive against rabbit erythrocytes. Another hemolysin[3,4] is similar in activity but immunologically distinct from alpha hemolysin; a fourth (delta)[1,5] is not demonstrable in broth cultures but produces lysis of human erythrocytes in addition to those of rabbits and sheep when cultures are grown on blood-agar plates.

Selbie and Simon[6] have shown that alpha-hemoly-

*From the Department of Medicine, University of Illinois College of Medicine.

†Associate professor of medicine, University of Illinois College of Medicine.

‡Professor of medicine and head, Department of Medicine, University of Illinois College of Medicine.

§Research assistant, University of Illinois College of Medicine.

sin production is the most important index in vitro of the virulence of staphylococci for mice. Cruickshank[7] found alpha-hemolysin-producing strains highly pathogenic for rabbits, and others[2,8-10] have observed that this exotoxin is produced by staphylococci that are pathogenic for man.

In a recent study of respiratory-tract infections among patients with poliomyelitis who had a tracheotomy performed because of respiratory paralysis, staphylococci were found to be the most common bacterial species encountered.[11,12] Alpha-hemolysin production by these strains was studied, and the results were compared with the coagulase test and correlated with the anatomic site from which the strain was isolated. Additional comparisons of coagulase and alpha-hemolysin production among strains from a variety of sources have been made, and these data are also presented.

Materials and Methods

The patients suffering from poliomyelitis with respiratory paralysis from whom staphylococci were isolated were hospitalized at the Chicago Municipal Contagious Disease Hospital. Secretions for culture were obtained from the nose, throat and trachea when tracheotomy was performed and subsequently twice each week. In the fatal cases cultures were obtained from the lungs and regional lymph nodes at autopsy. Other patients from whom staphylococci were isolated for study were cared for at the Research and Educational Hospitals.* In addition to the data presented here, the strains were characterized by colony morphology, pigment production, phage typing and a gram-stained smear. Coagulase tests were performed by the use of 0.3 cc. of a 1:10 solution of fresh rabbit plasma in saline solution and 0.1-cc. inoculum from an eighteen-hour broth culture of organisms. The tubes were incubated at 37°C. and examined at thirty and sixty minutes and then at six, eighteen and twenty-four hours. The formation of a clot within twenty-four hours was considered a positive test for coagulase.

Alpha-hemolysin production was determined by a modification of the method described by McFarlan.[8] The culture was incubated in tryptose phosphate broth in an atmosphere of 30 per cent carbon dioxide at 37°C. for forty-eight hours. To determine the alpha-hemolysin titer the broth cultures were centrifuged and the supernatant was used in a final dilution in physiologic saline solution of 1:2 and 1:10 and thenceforth in serial fourfold dilutions to 1:2560. Fresh rabbit erythrocytes were washed three times with saline solution, and then 0.6 cc. of a 2 per cent suspension of cells was added to an equal volume of the diluted culture supernatant. The tubes were placed in a water bath at 37°C. for an hour and then refrigerated at 4°C. overnight, to allow the erythrocytes to settle and facilitate reading of the hemolysis produced. The titer was taken as the greatest dilution of supernatant fluid from a broth culture that produced at least 50 per cent hemolysis. The end point was usually determined by gross inspection, but checks were made in a Coleman junior spectrophotometer. Control tubes were always included for observation of spontaneous hemolysis. Immunologic identification of alpha hemolysin was made by the method of Gillespie and Simpson,[13] with a refined staphylococcal antitoxin, 1250 units per cubic centimeter.† The identity of other hemolysins was determined on rabbit, sheep and human blood-agar plates as reported by Elak and Levy.[2]

Table 1. *Tests for Virulence of Staphylococci Isolated from Different Levels of the Respiratory Tract of Patients after Tracheotomy Because of Respiratory Paralysis from Poliomyelitis.*

Source	Total No. of Strains	No. of Hemolysin-Positive Strains	Alpha-Hemolysin-Positive Titer		No. of Coagulase-Positive Strains	Coagulase-Positive Strains Producing Alpha Hemolysin
			1:40 or less	1:160 or more		
			%	%		%
Nose	47	15(32%)	85	15	22(47%)	68
Throat	18	9(50%)	67	33	13(72%)	69
Trachea	136	105(78%)	37	63	112(82%)	94
Lungs (autopsy)	16	13(82%)	22	78	15(93%)	87

Results

Staphylococci isolated from patients with poliomyelitis are considered according to the anatomic location from which the strains were cultured (Table 1). A third of the strains cultured from the noses of these patients produced alpha hemolysin, and as the site from which the strains were isolated descended in the respiratory tract, there was a progressive increase in the proportion that were alpha-hemolysin positive; half the strains from throats, more than three fourths from the trachea, and 13 of 16 strains from the lungs produced an appreciable amount of alpha hemolysin. Forty-seven per cent of the staphylococci obtained from the nose were coagulase positive. As with alpha hemolysin the percentage of coagulase-positive staphylococci increased as the site descended in the respiratory tract to 72, 82 and 93 per cent of the strains from the throats, trachea and lungs respectively. Among the coagulase-positive strains from the upper respiratory tract (that is, the nose and throat) nearly a third failed to produce a measurable amount of alpha hemolysin. Thus, only 30 per cent of the staphylococci from the nose and 50 per cent from the

*Miss Mary Turner and Miss Elizabeth Bond, of the Bacteriology Laboratory, furnished these cultures.

†Kindly supplied by Burroughs Wellcome and Company, Tuckahoe, New York.

throat were indicated as virulent by both tests. On the other hand, approximately 90 per cent of coagulase-positive strains from the lower respiratory tract produced alpha hemolysin, and 77 and 82 per cent from the trachea and lungs respectively were virulent by both criteria. This difference between the upper and lower respiratory tract in the number of coagulase-positive strains that produced alpha hemolysin is highly significant statistically ($\chi^2 = 7.6$). Thus, the lence of the strain as judged from the site of implantation. As shown in Table 1, 85 and 67 per cent of the alpha-hemolysin-positive strains isolated from the nose and throat, respectively, produced a low titer of the lysin, 1:40 or less, whereas 63 and 78 per cent of the strains from the trachea and lungs, respectively, produced alpha hemolysin in a titer of 1:160 or greater. These differences are statistically highly significant ($\chi^2 = 14.2$; d.f. = 3). Hence, not only

TABLE 2. *Comparison of Coagulase and Alpha Hemolysin for 457 Strains from Various Sources.*

SOURCE	TOTAL NO. OF STRAINS	COAGULASE-POSITIVE STRAINS		COAGULASE-NEGATIVE STRAINS	
		ALPHA-HEMOLYSIN POSITIVE	ALPHA-HEMOLYSIN NEGATIVE	ALPHA-HEMOLYSIN POSITIVE	ALPHA-HEMOLYSIN NEGATIVE
Nose	172	64	18	9	81
Throat	39	21	9	1	8
Trachea	145	108	8	3	26
Lung	16	13	2	0	1
Eye & ear	5	1	0	0	4
Wound	24	12	10	0	2
Osteomyelitis	15	13	2	0	0
Tissue biopsy	5	2	2	0	1
Blood	27	8	3	1	15
Cerebrospinal fluid	5	2	1	0	2
Urine	2	2	0	0	0
Stool	2	1	1	0	0
Totals	457	247(82%)	56(18%)	14(9%)	140(91%)

indication of virulence according to alpha-hemolysin production appeared to align more closely with the clinical and pathological estimation of virulence than a positive coagulase test did.

The production of alpha hemolysin by staphylococci from the upper respiratory tract was limited

TABLE 3. *Distribution of Strains of Staphylococci According to Their Titer of Alpha-Hemolysin Production.*

ALPHA-HEMOLYSIN TITER	COAGULASE-POSITIVE STRAINS		COAGULASE-NEGATIVE STRAINS		TOTALS
	NUMBER	PERCENTAGE	NUMBER	PERCENTAGE	
Negative	55	18.0	140	91.0	191(41.8%)
1:2	22	7.3	8	5.2	34(7.4%)
1:10	32	10.6	2	1.3	34(7.4%)
1:40	62	20.4	3	1.9	65(14.2%)
1:160	50	16.5	0	0	50(11.0%)
1:640	36	11.8	0	0	36(7.9%)
1:2560	46	15.4	1	0.6	47(10.3%)
Totals	303		154		457

to strains that were coagulase positive. In the lower respiratory tract, however, 2 (8 per cent) of the coagulase-negative strains were alpha-hemolysin positive. In this respect the alpha-hemolysin test again agreed with the clinical findings better than the coagulase test.

The titer of alpha-hemolysin production also appeared to have a direct correlation with clinical virulence of the strain as judged from the site of implantation. As shown in Table 1, 85 and 67 per cent of the alpha-hemolysin-positive strains isolated from the nose and throat, respectively, produced a low titer of the lysin, 1:40 or less, whereas 63 and 78 per cent of the strains from the trachea and lungs, respectively, produced alpha hemolysin in a titer of 1:160 or greater. These differences are statistically highly significant ($\chi^2 = 14.2$; d.f. = 3). Hence, not only was the alpha-hemolysin test more discriminatory in identifying clinically virulent strains than the coagulase test but also the titer of alpha hemolysin was a helpful indication of the clinical importance of the strain.

Comparison of alpha hemolysin and the coagulase test for a larger number of strains from a variety of sources is presented in Table 2. Ninety-five per cent of the strains that produced alpha hemolysin were coagulase positive. Eighty-two per cent of coagulase-positive strains produced alpha hemolysin whereas most coagulase-negative strains failed to do so.

A large proportion of alpha-hemolysin negative strains (46 per cent of coagulase-positive and all coagulase-negative strains) was found among cultures from wounds and tissue biopsies. It appears likely that the majority of these strains were contaminants. The next most frequent sites of coagulase-positive but alpha-hemolysin-negative organisms were noses, throats and blood cultures — 31 per cent of the coagulase-positive strains. In these cases the clinical estimation of the strains was toward low pathogenicity. The least discrepancy between the coagulase and alpha-hemolysin tests was among the cultures from the trachea and lungs, and from patients with osteomyelitis. Table 3 shows the distribution of the strains from all sources according to their alpha-hemolysin titer. Three populations appear to exist among the strains, with peaks at titers of 0, 1:40 and 1:2560.

The virulence, as determined by coagulase and alpha hemolysin in relation to sensitivity or resistance to some antibiotics in vitro, is given for a few strains observed to lose the capacity to produce either coagulase or alpha hemolysin.

An investigation has been made of the variation in

TABLE 4. *Comparison of the Virulence of Staphylococci As Measured by Coagulase and Alpha-Hemolysin Production among Strains Sensitive and Resistant to Antibiotics.*

ANTIBIOTIC	SENSITIVITY	COAGULASE-POSITIVE STRAINS			COAGULASE-NEGATIVE STRAINS		
		NUMBER	ALPHA-HEMOLYSIN POSITIVE	ALPHA-HEMOLYSIN NEGATIVE	NUMBER	ALPHA-HEMOLYSIN POSITIVE	ALPHA-HEMOLYSIN NEGATIVE
	units or microgm./cc.						
Penicillin	≤0.12	12	8	4	11	3	8
	>250.0	12	10	2	12	1	11
Chlortetracycline	≤1.0	9	8	1	11	5	6
	>125.0	12	10	2	12	0	12
Erythromycin	≤0.49	12	10	2	12	1	11
	>250.0	12	12	0	13	3	10
Total sensitive		33	26	7	34	9	25
Total resistant		36	32	4	37	4	33

in Table 4. The strains were selected for study on the basis of the coagulase reaction and their antibiotic sensitivity, but all were obtained from patients and

TABLE 5. *Variation in the Test for Alpha-Hemolysin Production from Repetition.*

FIRST DETERMINATION		SECOND DETERMINATION	
NO. OF STRAINS POSITIVE	NO. OF STRAINS NEGATIVE	NO. OF STRAINS POSITIVE	NO. OF STRAINS NEGATIVE
38	0	38	0
0	29	3	26

none were made resistant in vitro. Among the coagulase-positive strains there was no statistically significant difference in the number that were alpha-hemolysin positive and alpha-hemolysin negative so far as antibiotic sensitivity or resistance was concerned. However, among the coagulase-negative strains there were significantly more that produced alpha hemolysin among those that were sensitive to antibiotics

TABLE 6. *Variation among Individual Colonies.*

NO. OF STRAINS	NO. OF COLONIES	COAGULASE STATUS	ALPHA-HEMOLYSIN TITER IN PARENT CULTURE	ALPHA-HEMOLYSIN SUBCULTURE OF INDIVIDUAL COLONIES		
				NO. POSITIVE	MEDIAN TITER	NO. NEGATIVE
2	40	Positive	2560	40	640	0
2	40	Positive	10	39	40	1
2	40	Positive	0	23	2	17
2	40	Negative	40	40	40	0
2	40	Negative	0	1	2	39

($\chi^2 = 4.8$), largely owing to the difference in chlortetracycline sensitivity ($\chi^2 = 6.96$) among the strains. Six coagulase-positive and alpha-hemolysin-positive strains made resistant to chlortetracycline by serial transfer in antibiotic containing broth in vitro were

the results of testing for alpha hemolysin under a variety of circumstances (Tables 5-8). A blind second determination performed on random days on 38 known positive and 29 known negative strains indicated that the positive strains could be identified without error, although the median titer was lower in the second dermination. When the test was repeated

TABLE 7. *Variation from in Vitro Subculture.*

NO. OF STRAINS	NO. OF SUCCESSIVE SUBCULTURES	NO. OF GENERATIONS		
		TITER FOURFOLD < PARENT CULTURE	SAME TITER AS PARENT CULTURE	TITER FOURFOLD > PARENT CULTURE
5	10	3	38	4

with hemolysin-negative strains 3, or 10 per cent, were found to have a low positive titer.

The variation in alpha-hemolysin production among individual colonies was evaluated by study of 20 colonies each from strains that were coagulase positive with high and low hemolysin titers and 1 strain that was hemolysin negative. Similarly, colonies from coagulase-negative strains that were alpha-

TABLE 8. *Variation by Use of Erythrocytes from Different Rabbits.*

NO. OF STRAINS	NO. OF RABBIT DONORS	NO. OF TIMES RESULT OCCURRED		
		FOURFOLD < MEDIAN TITER	AGREEMENT	FOURFOLD > MEDIAN TITER
10	5	2	45	3

hemolysin positive and negative were used. Progeny from positive strains had a titer resembling the parent culture with rare exceptions. However, 60 per cent of the cultures propagated from individual colonies of the 2 coagulase-positive, alpha-hemolysin-negative

strains and 1 colony culture (2.5 per cent) from the 2 coagulase-negative, alpha-hemolysin-negative strains, were observed to produce a low titer of hemolysin.

The tendency for a culture to maintain its alpha-hemolysin titer at least temporarily in vitro was demonstrated by a small number of strains that were transferred daily for ten days in tryptose phosphate broth without a significant alteration in the measured titer of alpha hemolysin. Eighty-five per cent of the 10 successive transfer generations of 5 strains yielded the same titer as the parent culture. The use of erythrocytes from various rabbit donors also made no important difference in the determination of the titer of a culture.

The immunologic and biologic procedures used to confirm the identity of alpha hemolysin were conclusive by the criteria of Gillespie and Simpson[19] and Elak and Levy.[2] Most of the alpha-toxigenic cultures also produced delta hemolysin that caused hemolysis of human erythrocytes on blood-agar plates. However, this was not an absolute finding since both the alpha and delta hemolysins occurred in the absence of the other. Since delta hemolysis is not produced in broth culture, the hemolysis of rabbit erythrocytes, as reported here, can be assigned to alpha hemolysin. No attempt was made to correlate the occurrence or the titers of the various hemolysins of staphylococci.

Discussion

Determination of the virulence of staphylococci in vitro is at best a relative classification and must be correlated with the particular host, the type of illness, the anatomic site of isolation and the nature of the pathologic lesion. The coagulase test has been accepted as a simple method for screening strains of staphylococci for potential pathogenicity. Spink and Vivino[14] demonstrated that coagulase-positive strains were able to resist the bactericidal action of human defibrinated blood whereas coagulase-negative strains were killed in large numbers. Hale and Smith[15] noted that coagulase-positive strains resisted phagocytosis in comparison with coagulase-negative strains, and Rogers and Tompsett[16] found that micro-organisms from coagulase-positive strains were able to proliferate within leukocytes after phagocytosis whereas organisms from coagulase-negative strains were lysed.

The role of coagulase per se in infections in vivo, however, is not entirely clear. It has been observed[17] that most coagulase-positive strains consist of a mixture of positive and negative variants. Only a small proportion of coagulase-positive strains give high yields of coagulase, and some coagulase-negative strains may have coagulase-positive variants.[17,18] Tager and Hale[18] studied the quantitative production of coagulase according to the site and type of lesions from which the strains were isolated; there were significantly more strains with a high coagulase titer among cultures from the body surfaces than among strains isolated from inflamed lesions. Thus, the quantitative aspects of coagulase production may not be related to the severity of the pathologic lesions, but the results of animal experiments by Smith and his colleagues[19] suggest that the initial infectivity of staphylococci is largely dependent on coagulase. The progression of the lesion then might be influenced by other virulence factors such as alpha hemolysin.

The data presented here show, as others have found, that alpha toxigenicity occurs principally among coagulase-positive strains. The quantities of coagulase and alpha hemolysin produced by the strain, however, need have no correlation.[18] Nearly a fifth of the coagulase-positive strains in our studies did not produce appreciable amounts of alpha hemolysin. In these cases alpha hemolysin production correlated with the clinical estimation of pathogenicity of the strain better than coagulase. Autopsy findings in the fatal cases will be reported elsewhere.[12] Alpha hemolysin was a discriminatory test for virulence among coagulase-positive strains and indicated in addition a small percentage of toxigenic coagulase-negative strains, which, with rare exceptions, had low titers. Most other workers, principally in England[2,7-9,13,20-23] have found that 90 to 100 per cent of coagulase-positive strains of human origin produced alpha hemolysin. Elak and Levy,[2] however, reported that only 87 per cent of coagulase-positive strains from the skin produced alpha hemolysin. In most of these investigations coagulase-negative strains were found to be nontoxigenic.

In the present studies the titer of alpha hemolysin produced by a strain appeared to have an important relation to the site of the infection. If one were to classify the strains of staphylococci according to the three peaks in their distribution by alpha hemolysin titer, at 0, 1:40 and 1:2560, and designate all the strains with a negative titer, but coagulase positive, as "potential pathogens," those with a titer up to 1:40 as "virulent" and strains with a higher titer as "highly virulent," 29 per cent of staphylococci would be placed in each of the last two groups, and 12 per cent in the first; 30 per cent of strains in this series were nontoxigenic and coagulase negative. Less than 1 per cent of the "highly virulent" and an eighth of the "virulent" strains would be coagulase negative, an average of 6 per cent of pathogenic strains being coagulase negative. Among the coagulase-positive strains 47 per cent might be considered "highly virulent," and 18 per cent only "potentially pathogens." In this study most of the latter were inhabitants of the nose.

Among the toxigenic strains nearly all the individual colonies produced alpha hemolysin, whereas the nontoxigenic coagulase-positive strains were composed of a mixture of organisms, some of which produced a low titer of alpha hemolysin.

Selbie and Simon[8] found that virulence for mice

was not great until an alpha-hemolysin titer of 1:5 was reached, but pathogenicity increased progressively beyond this point. Tager and Hale,[18] in their study of 242 strains isolated from human beings were unable to show a significant difference in alpha-hemolysin titer among strains from different sources, and in this respect their results and ours are directly contradictory without an apparent explanation for the difference.

The fact that antibiotic-sensitive and antibiotic-resistant strains of staphylococci isolated from patients did not differ in these two criteria of pathogenicity, in contrast to the loss of virulence by strains made resistant to chlortetracycline in vitro, also indicates the biologic difference between naturally occurring resistant strains and those created in the laboratory. On the other hand the percentage of coagulase-positive strains found to be nonproducers of alpha hemolysin — 18 per cent over-all and 31 per cent of strains from the nose and throat — is the highest recorded in the literature for strains from human sources. Since nearly all the preceding studies were performed before antibiotic-resistant strains were predominant and since most of the strains that we studied were highly resistant to one or more antibiotics, it might be that the in vivo selection of antibiotic-resistant strains has also decreased the percentage of alpha toxigenic ones. This aspect deserves additional study.

The determination of alpha hemolysin appears to be sufficiently reproducible for use. It is not recommended as a substitute for the coagulase test, but if the alpha-hemolysin titer is determined as an adjunct it might enable better identification of pathogenic strains of staphylococci and rarely substantiate the virulence of a coagulase-negative strain.

Summary and Conclusions

A study of 217 strains of staphylococci isolated from different levels of the respiratory tract of patients with respiratory paralysis from poliomyelitis was made to correlate the estimation of virulence as judged by the site of implantation, coagulase test and alpha-hemolysin titer. Similar observations were made on 240 additional strains from various sources. Alpha hemolysin was more discriminatory than the coagulase test, and in the patients with respiratory paralysis the former correlated better with the clinical estimation of pathogenicity. Among the coagulase-positive strains from the lower respiratory tract there was a statistically significant increase in the number with a high titer of alpha hemolysin as compared with those from the nose and throat.

Among strains from various sources a high percentage of coagulase-positive, alpha-hemolysin negative strains was recovered from superficial wounds, tissue biopsies and blood cultures as well as from the upper respiratory passages. Eighteen per cent of all coagulase-positive strains were alpha-hemolysin negative, whereas 9 per cent of coagulase-negative strains produced a low titer of alpha hemolysin. The antibiotic sensitivity to penicillin, chlortetracycline and erythromycin made no apparent difference in the alpha-hemolysin production of a group of coagulase-positive strains except in cultures that had been made resistant in vitro. The high percentage of alpha-hemolysin-negative, coagulase-positive strains in our observations, however, may have been due to the extensive clinical use of antibiotics.

The variations in the test for alpha hemolysin were observed according to repetition, difference among individual colonies, in vitro transfers of the culture and the rabbit as donor of erythrocytes. Determination of the alpha-hemolysin titer is a useful adjunct to the coagulase test in identifying pathogenic strains of staphylococci in vitro.

References

1. Williams, R. E. O., and Harper, G. J. Staphylococcal haemolysins on sheep blood agar with evidence for fourth haemolysin. *J. Path. & Bact.* 59:69-78, 1947.
2. Elek, S. D., and Levy, E. Distribution of haemolysins in pathologic and non-pathologic staphylococci. *J. Path. & Bact.* 62:541-554, 1950.
3. Morgan, F. G., and Graydon, J. J. Toxins of staphylococcus, with special reference to estimation of potency. *J. Path. & Bact.* 43: 385-401, 1936.
4. Smith, M. L., and Price, S. A. Staphylococcus alpha haemolysin. *J. Path. & Bact.* 47:379-393, 1938.
5. Marks, J. Recognition of pathogenic staphylococci; with notes on non-specific staphylococcal hemolysin. *J. Path. & Bact.* 64:175-186, 1952.
6. Selbie, F. R., and Simon, R. D. Virulence to mice of *Staphylococcus pyogenes*: its measurement and its relation to certain in vitro properties. *Brit. J. Exper. Path.* 33:315-326, 1952.
7. Cruickshank, R. Staphylocoagulase. *J. Path. & Bact.* 48:295-303, 1937.
8. McFarlan, A. M. Incidence of pathogenic staphylococci in nose. *Brit. M. J.* 2:939-941, 1938.
9. Cowan, S. T. Classification of staphylococci by precipitation and biological reactions. *J. Path. & Bact.* 46:31-45, 1938.
10. Bryce, L. M., and Rountree, P. M. Production of B-toxin by staphylococci. *J. Path. & Bact.* 43:175-189, 1936.
11. Kofman, S. Lepper, M. H., Jackson, G. G., and Dowling, H. F. Unpublished data.
12. Lepper, M. H., Szanto, P. B., Kofman, S., Jackson, G. G., and Dowling, H. F. Unpublished data.
13. Gillespie, W. A., and Simpson, P. M. Pathogenic staphylococci: detection of alpha-lysin production on rabbit and sheep-blood agar plates. *Brit. M. J.* 2:902, 1948.
14. Spink, W. W., and Vivino, J. J. Coagulase test for staphylococci and its correlation with resistance of organism to bactericidal action of human blood. *J. Clin. Investigation* 21:353-356, 1942.
15. Hale, J. H., and Smith, W. Influence of coagulase on phagocytosis of staphylococci. *Brit. J. Exper. Path.* 28:209-216, 1945.
16. Rogers, D. E., and Tompsett, R. Survival of staphylococci within human leukocytes. *J. Exper. Med.* 95:209-230, 1952.
17. Smith, D. D., Morrison, R. B., and Tominski, I. Isolation of variants of *Staphylococcus aureus* giving high and low yields of coagulase. *J. Path. & Bact.* 64:367-373, 1952.
18. Tager, M., and Hale, H. B. Quantitative coagulase and toxin production by staphylococci in relation to clinical source of organisms. *Yale J. Biol. & Med.* 20:41-49, 1947.
19. Smith, W., Hale, J. H., and Smith, M. M. Role of coagulase in staphylococcal infections. *Brit. J. Exper. Path.* 28:57-67, 1947.
20. Gillespie, E. H., Devenish, E. A., and Cowan, S. T. Pathogenic staphylococci. *Lancet* 2:870-873, 1939.
21. Schwabacher, H., Cunliffe, A. C., Williams, R. E. O., and Harper, G. J. Hyaluronidase production by staphylococci. *Brit. J. Exper. Path.* 26:124-129, 1945.
22. Christie, R., North, E. A., and Parkin, G. A. Criteria of pathogenicity in staphylococci. *Australian J. Exper. Biol. & M. Sc.* 24: 73-78, 1946.
23. Williams, R. E. O., and Harper, G. J. Determination of coagulase and alpha haemotoxin production by staphylococci. *Brit. J. Exper. Path.* 27:72-81, 1946.

TREATMENT OF MENINGITIS DUE TO FRIEDLÄNDER'S BACILLUS*

Review of Specific Therapy and Report of a Case Successfully Treated with Streptomycin and Sulfadiazine That Had Failed to Respond to Chlortetracycline

A. L. Loomis Bell, Jr., M.D.†

NEW YORK CITY

THE Friedländer bacillus (*Klebsiella pneumoniae*) is a relatively rare invader of the central nervous system, but, when encountered, meningitis due to this organism constitutes a major therapeutic problem. Only 119 cases of the infection have been described in the world literature[1] since this organism was first described by Friedländer in 1882, and the majority of these cases have appeared in recent years as isolated case reports relating experience with the newer antibiotic agents. A review of these cases reveals that recovery from the infection, virtually nonexistent before the era of specific therapy, has been attributed to the sulfonamides, streptomycin, chlortetracycline and chloramphenicol. However, no one of these agents is universally effective in the treatment of the infection, and the over-all mortality remains about 50 per cent. As a result there is no general agreement regarding specific therapy, and it has seemed pertinent to review the management and specific therapy of the disease and to report studies in a typical case.

Case Report

A 73-year-old widow (A.868) was admitted to the hospital complaining of shooting pains in both legs of 2 months' duration associated with pains of the shoulder and neck and a mild anemia. The urine was positive for Bence-Jones protein, and the patient was admitted to the hospital with a tentative diagnosis of multiple myeloma.

Physical examination showed a thin, elderly, deaf woman who was somewhat pale but in no acute distress. Both eardrums were dull, retracted and scarred. There was no mastoid tenderness. The nose and throat were normal. The fundi appeared normal. The remainder of the physical examination was unremarkable.

The temperature was 98.6°F., and the pulse 80. The blood pressure was 155/70.

Urinalysis was negative, with numerous specimens negative for Bence-Jones protein. Examination of the blood revealed a red-cell count of 2,650,000, and a white-cell count of 16,500, with 82 per cent neutrophils, 12 per cent lymphocytes and 5 per cent monocytes. Blood urea nitrogen and sugar and serum proteins were normal. Liver-function tests were within normal limits. The blood Kolmer reaction was negative. The sedimentation rate was 60 mm. per hour. An electrocardiogram was interpreted as normal. X-ray examination of the bony skeleton revealed no abnormalities, except mild osteoarthritic changes of the spine.

The admission impression of multiple myeloma was not substantiated by the laboratory data and subsequent course. On the 2d hospital day, a temperature of 101°F. developed, subsequently rising to 102-103°F. in daily elevations for the first 9 days of hospitalization. There were no localizing symptoms or signs. The white-cell count ranged from 14,000 to 21,000 during this period, with 82 to 97 per cent neutrophils. Urine cultures were negative. Two blood cultures taken on the 4th and 6th hospital days grew out gram-negative, nonmotile, encapsulated bacilli in abundant round, translucent, mucoid, grayish-white colonies. Lactose, maltose, sucrose and salicin were readily fermented, with production of acid and gas. Mannitol and sorbitol were not fermented. Tests for indole and methyl-red formation were positive. The Voges–Proskauer reaction was negative. By means of the quellung reaction with type-specific serum, the organism was identified as a Group A Friedländer bacillus.

Because the organism was sensitive to 0.15 microgm. of chlortetracycline[2] per cubic centimeter the patient was given 250 mg. of the drug by mouth every 6 hours beginning on the 10th hospital day. Oral therapy was stopped after 4 days of treatment because of nausea and vomiting, and intravenous treatment continued, 100 mg. every 6 hours for 3 days. Within 24 hours of the start of therapy the temperature returned to normal and remained normal throughout the 7-day course of treatment.

The patient remained afebrile and asymptomatic until, on the 22d hospital day, a temperature of 102°F. again developed. A tender, red subcutaneous mass overlying the right deltoid muscle was the only noteworthy physical finding. A blood culture at this time grew out Friedländer's bacilli. The abscess was incised and drained of thick, yellow material, which grew out the same organism on culture. On the following day the temperature again rose to 103°F., and a 2d tender, red subcutaneous mass was discovered overlying the right mastoid area. The blood culture was again positive for Friedländer's bacillus. Examination of the eardrums gave no evidence of inflammation. X-ray examination of the mastoid processes was interpreted as within normal limits. The abscess was opened and drained, and the depths of the abscess explored for communication with the underlying mastoid bone. No break in the periosteum was found. Friedländer's bacilli were readily cultured from the abscess. Chlortetracycline was administered again intravenously, 100 mg. every 6 hours. The febrile and symptomatic response was prompt. On the 36th hospital day, after 14 days on this regimen, chlortetracycline was stopped.

The patient remained afebrile and without complaints for 14 days. Discharge from the hospital was contemplated when, without premonitory symptoms, severe frontal headache, stiff neck, vomiting and tenderness over the right mastoid bone developed suddenly on the 49th hospital day (Fig. 1). On examination she was acutely ill with a temperature of 102°F. The right eardrum was reddened superiorly and posteriorly. Exquisite tenderness was present over the right mastoid process in the area of the scar from the previous incision and drainage. Nuchal rigidity was present, and positive Kernig and Brudzinski signs were elicited. Examination of the eye grounds revealed loss of physiologic cupping bilaterally. The white-cell count was 19,400, with 87 per cent neutrophils. A lumbar puncture was performed, with an initial cerebrospinal-fluid pressure of over 500 mm. of water; the fluid was white and turbid, with 2380 white cells per cubic millimeter, 87 per cent of which were neutrophils. Friedländer's organisms were readily identified in the spinal fluid by smear and later by culture.

Under general anesthesia the abscess overlying the right mastoid process was opened and drained of thick, yellow material. A simple mastoidectomy was performed. The antrum contained thick pus, and on further exploration, the right lateral sinus was found to be thrombosed. Both areas were drained. Cultures taken from the subcutaneous abscess, mastoid antrum and lateral sinus all grew out Friedländer's bacillus. Immediately after the operation, 200 mg. of chlortetracycline was administered intravenously every 6 hours. Although the febrile response was prompt, there was no improvement in the patient's over-all condition. In 48 hours there was no change in the spinal-fluid findings, and

*From the Department of Medicine, St. Luke's Hospital.

†Instructor in medicine, Columbia University College of Physicians and Surgeons; assistant attending physician, St. Luke's Hospital.

Friedländer's organisms were readily demonstrated on smear and culture. At that time simultaneous blood and spinal-fluid levels of chlortetracycline taken 1½ hours after an intravenous dose indicated a blood level of more than 8.0 microgm. and a spinal-fluid level of less than 0.5 microgm. per cubic centimeter.[2] Since the spinal-fluid level was inadequate for the sensitivity of the organism the dose was increased to 400 mg. every 6 hours intravenously on the 51st hospital day. Twenty-four hours later the spinal fluid still contained abundant Friedländer bacilli, and, despite a normal temperature, the patient's clinical condition had worsened. Chlortetracycline levels of specimens collected exactly as on the preceding day again revealed the marked disparity between blood and spinal-fluid concentration.

Since the organism was sensitive to streptomycin the patient was given 0.5 gm. of that drug every 6 hours intramuscularly and 0.1 gm. intrathecally every day. In addition 5 gm. of sulfadiazine was administered intravenously each day. Dramatic clinical improvement was apparent within 12 hours. Spinal-fluid culture was sterile within 12 hours. Spinal-fluid concentrations of streptomycin obtained 24 hours after an intrathecal dose and 6 hours after an intramuscular dose were well in excess of the sensitivity of the organism. After 48 hours on the streptomycin regimen the intramuscular dose was reduced to 0.5 gm. every 12 hours. Intrathecal administration of streptomycin was discontinued after 7 days, and sulfadiazine was stopped after 18 days. Intramuscular injection of streptomycin was continued for 14 days. Over this period, there was rapid clinical improvement, and convalescence was entirely uneventful. At follow-up study 4 years later the patient was enjoying good health, without evidence of recurrence of the infection.

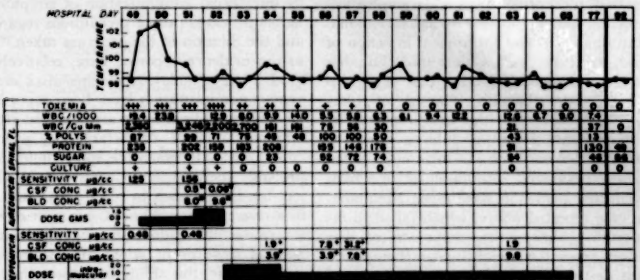

FIGURE 1. *Course of a Patient with Meningitis Due to Friedländer's Bacillus.*

DISCUSSION

Undoubtedly, the right middle ear and mastoid process served as the primary focus of infection in this case. During the period of bacteremia and before there was evidence of meningitis, chlortetracycline successfully controlled the bacteremia but obviously did not sterilize the primary focus of infection. If this primary focus had been recognized and drained earlier, it is probable that the organism would never have gained entry into the central nervous system. It is equally probable that the meningeal infection could not have been cured by specific therapy without surgical drainage of the primary focus. It is of some importance, then, in the management of Friedländer's meningitis to recognize that the organism rarely if ever primarily invades the central nervous system, and to search for a primary focus. The probable focus of the infection in the cases reported in the literature[1,3-5] is the upper respiratory tract in the majority of cases. Pneumonia, bronchitis and traumatic and operative wounds have served as the portal of entry in a smaller number of cases.

In the case reported above, the organism was susceptible to chlortetracycline in a concentration of 1.25 and 1.56 microgm. per cubic centimeter. Chlortetracycline did not reach the spinal fluid in therapeutic concentration despite very high simultaneous blood levels. The low spinal-fluid levels measured in this case are thought to reflect in vivo levels of the drug since both blood and spinal fluid were collected simultaneously and analyzed immediately.[6] Furthermore, it is evident from the repeatedly positive spinal-fluid cultures during the seventy-two hours of chlortetracycline therapy that the drug did not reach the meningeal infection in therapeutic concentration despite the observed drop in temperature. Although streptomycin and sulfadiazine were undoubtedly responsible for the recovery of this patient, as well as others reported in the literature,[7] meningitis due to strains resistant to both sulfadiazine and streptomycin has been reported.[7,8]

Difficulties arise in evaluating the effectiveness of specific therapy from analysis of the case reports in the literature.[1,3-5] In most cases more than one antibiotic agent has been used simultaneously, a practice that complicates clinical evaluation of therapy, and in only a few cases are data on blood or spinal-fluid levels of the drug or the sensitivity of the organism to the antibiotic reported. However, there can be little

question that the use of sulfonamides has reduced the mortality strikingly from an almost uniformly fatal disease to about 50 per cent. No cases are recorded in which the addition of penicillin clearly influenced the course of the disease, and the outcome was fatal in the single case in which penicillin constituted the total specific therapy. It is impossible to evaluate the overall effectiveness of streptomycin from a review of case reports since this drug has not been used successfully without one of the sulfonamides, and the mortality after combined sulfonamide and streptomycin treatment does not differ significantly from that of patients receiving sulfonamide therapy alone. A single case has been treated successfully with chloramphenicol after the infection had failed to respond to sulfonamides and intramuscular and intrathecal injection of penicillin and streptomycin.[8] Chlortetracycline has been used in the treatment of 1 other case of meningitis due to Friedländer's bacillus. The role of chlortetracycline in the recovery of this case, reported by Thompson and his associates,[1] is dubious since the drug was administered only early in the course of the disease and intrathecal and intramuscular injections of streptomycin and penicillin were given simultaneously. In the case reported above, which failed to respond to chlortetracycline, it was demonstrated that the drug did not reach the spinal fluid in therapeutic concentrations despite very high simultaneous blood levels.

It is apparent from a view of these case reports that no one antibiotic or combination of antibiotics is uniformly effective and specific therapy remains generally unsatisfactory as compared to that of meningitis due to other bacteria.

A rational approach to the problem of specific therapy must include proper selection of the antibiotic agent on the basis of sensitivity of the strain of the organism identified, and effective administration of the drug to assure therapeutic concentration in the spinal fluid. The Friedländer bacillus is almost uniformly resistant to penicillin,[9] which is therefore of no value. The sulfonamides, particularly sulfadiazine, have been shown to be effective in the treatment of experimental infections with Friedländer's bacillus,[10] and the striking reduction in mortality from meningitis warrants continued use of these drugs. However, organisms resistant to the sulfonamides are encountered frequently, and a favorable outcome can be expected in no more than 50 per cent of the cases. Sensitivity of the organism to streptomycin has been reported in a wide range of 0.05 to more than 1000 microgm. per cubic centimeter.[7,11] It is necessary, then, to determine the sensitivity of the organism to streptomycin before the usefulness of this antibiotic agent in a given case can be decided. The three closely related antibiotics tetracycline, chlortetracycline and oxytetracycline have all been shown to be about equally effective against experimental infections with Friedländer's bacillus.[12,13] Chloramphenicol has been effective against the organism in concentrations of 0.5 to 25 microgm. per cubic centimeter.[9]

A second important factor in the successful treatment of meningitis is the necessity for the antibiotic to reach the organism in the central nervous system in effective concentration. Sulfadiazine given parenterally will reach the spinal fluid in a concentration of 50 to 70 per cent of the serum level, whereas relatively little streptomycin diffuses into the spinal fluid after intramuscular administration of the drug.[11,14,15] Streptomycin, then, must be given intrathecally to produce dependable therapeutic levels for most organisms. The risk of producing nervous-system damage by intrathecal administration of streptomycin is negligible provided proper precautions regarding the dose and the dilution of the drug are taken.[16] In addition to the evidence reported here, relatively low spinal-fluid levels of chlortetracycline after oral and intravenous administration have been reported.[17,18] Similar low spinal-fluid levels are reported after parenteral administration of oxytetracycline, whereas tetracycline appears to reach the spinal fluid in greater and probably therapeutic concentration.[19] Chloramphenicol has been shown to reach the spinal fluid rapidly in a concentration 30 to 50 per cent of that noted in the serum after administration by mouth.[20,21] Since none of these preparations are recommended for intrathecal use, the ability of tetracycline and particularly chloramphenicol to diffuse into the spinal fluid in therapeutic concentration renders these drugs superior to chlortetracycline and oxytetracycline for the treatment of meningitis.

From these observations it is clear that as soon as the organism is identified its sensitivity to the several likely antibiotic agents must be determined. The antibiotic of choice must be given in a dose sufficient to assure a spinal-fluid concentration well in excess of the sensitivity of the organism. Although individual strains have been found highly resistant to streptomycin, sulfadiazine, chloramphenicol and tetracycline, it is likely that a given strain will be sensitive to one or more of these antibiotics in a concentration that can be achieved in the cerebrospinal fluid by parenteral administration, and by intrathecal administration as well when streptomycin is used. Because they appear to diffuse into the cerebrospinal fluid less readily oxytetracycline and chlortetracycline are less useful antibiotics in the treatment of meningitis.

Summary and Conclusions

A case of meningitis due to Friedländer's bacillus in which the primary focus of infection was in the middle ear, mastoid process and lateral sinus is reported. Chlortetracycline, given intravenously, failed to reach the spinal fluid in effective concentration despite very high simultaneous serum levels of the drug. The infection responded promptly to the intramuscular and intrathecal administration of streptomycin and intravenous injection of sulfadiazine.

The specific therapy of meningitis due to Friedländer's bacillus is reviewed. Although antibiotic therapy has reduced the mortality to about 50 per cent and recovery has been attributed to the sulfonamides, streptomycin and chloramphenicol, no one antibiotic or combination of antibiotics has been uniformly successful in treatment. An approach to the problem of the specific therapy of this disease is discussed.

A primary focus of infection is frequently associated with meningitis, and, when possible, surgical drainage of the focus is indicated.

I am indebted to Mrs. Helen Galgano for the bacteriologic studies.

References

1. Thompson, A. J., Williams, E. B., Jr., Williams, E. D., and Anderson, J. M. Klebsiella pneumoniae meningitis. *Arch. Int. Med.* 89:405-427, 1952.
2. Lepper, M. H., Dowling, H. F., Brickhouse, R. L., and Caldwell, E. R., Jr. Blood and cerebrospinal fluid concentrations of aureomycin after oral and intramuscular administration. *J. Lab. & Clin. Med.* 34:366-371, 1949.
3. Ransmier, J. C., and Major, J. W. Friedländer's bacillus septicemia and meningitis. *Arch. Int. Med.* 72:519-528, 1943.
4. Sadusk, J. R., Jr., Relman, A. S., Wagner, R. R., and Barnett, R. Friedländer's bacillus meningitis treated with streptomycin. *Am. J. Med.* 6:522-529, 1949.
5. Bombardier, J. P. La méningite à bacilles de Friedländer: étude comparative chez l'enfant et chez l'adulte. *Ann. d. méd.* 51:543-592, 1950.
6. Dowling, H. F., Lepper, M. H., Sweet, L. K., and Brickhouse, R. L. Studies on serum concentrations in humans and preliminary observations on treatment of human infections with aureomycin. *Ann. New York Acad. Sc.* 51:241,1948.
7. Ayvazian, L. F. Friedländer's bacillus meningitis successfully treated with streptomycin. *Am. J. Med.* 5:470-477, 1948.
8. Martin, R., Sureau, B., Le Mer, G., and Mousset, H. Méningite post-opératoire à bacilles de Friedländer: traitment par la chloromycétine après échec de la streptomycine. *Arch. franç. pédiat.* 7: 721-724, 1950.
9. Welch, H. *Principles and Practice of Antibiotic Therapy.* 699 pp. New York: Medical Encyclopedia, 1954.
10. Feinston, W. H., Williams, R. D., Wolf, M. S., Heinlington, E., and Crossley, M. L. Toxicity, absorption and chemotherapeutic activity of sulfadiazine. *Bull. Johns Hopkins Hosp.* 67:427-456, 1940.
11. Herrell, W. E., and Nichols, D. R. Clinical use of streptomycin: study of 45 cases. *Proc. Staff Meet., Mayo Clin.* 20:449-462, 1945.
12. English, A. R., P'an, S. Y., Gardocki, J. F., and Wright, W. A. Tetracycline — microbiological, pharmacological, and clinical evaluation. In *Antibiotics Annual, 1953-1954.* Edited by H. Welch and F. Marti-Ibáñez. 632 pp. New York: Medical Encyclopedia, 1953.
13. Kiser, J. S., et al. Comparative evaluation of chlortetracycline, oxytetracycline, and tetracycline in experimental infections. In *Antibiotics Annual, 1953-1954.* Edited by H. Welch and F. Marti-Ibáñez. 632 pp. New York: Medical Encyclopedia, 1953.
14. Heilman, D. H., Heilman, F. R., Hinshaw, H. C., Nichols, D. R., and Herrell, W. E. Streptomycin: absorption, diffusion, excretion, and toxicity. *Proc. Staff Meet., Mayo Clin.* 20:408-410, 1945.
15. Zintel, H. A., Flippin, H. F., Nichols, A. C., Wiley, M. M., and Rhoads, J. E. Studies on streptomycin in man. I. Absorption, distribution, excretion, and toxicity. *Am. J. M. Sc.* 210:421-430, 1945.
16. Weinstein, L., Goldfield, M., and Adams, D. Study of intrathecal chemotherapy in bacterial meningitis. *M. Clin. North America* 33: 1363-1378, 1953.
17. Herrell, W. C., and Heilman, F. R. Aureomycin: studies on absorption, diffusion and excretion. *Proc. Staff Meet., Mayo Clin.* 24:157-166, 1949.
18. Hall, W. Absorption and distribution of aureomycin in man: review of literature and study of concentration of aureomycin in serum, urine and cerebrospinal fluid after oral administration. *Ann. Int. Med.* 40:743-754, 1954.
19. Wood, O. S., Lipnis, C. F., and Dowling, H. F. Concentrations of tetracycline, chlortetracycline and oxytetracycline in cerebrospinal fluid after intravenous administration. In *Antibiotics Annual, 1953-1594.* Edited by H. Welch and F. Marti-Ibáñez. 632 pp. New York: Medical Encyclopedia, 1953. P. 00.
20. Ross, S., Bischoff, H., Preiser, W., and Orr, W. Some observations on absorption and excretion of aureomycin and chloramphenicol. *J. Clin. Investigation* 29:1050, 1949.
21. Gruhzit, O. M., Fisken, R. A., Reutner, T. F., and Martino, E. Chloramphenicol, antibiotic: pharmacological and pathological studies in animals. *J. Clin. Investigation* 29:943, 1949.

SPECIAL ARTICLE

A LIMITED-SCALE QUESTIONNAIRE STUDY OF NONFATAL-ACCIDENT CASES*

MARION GLEASON† AND PETER GLEASON, M.D.‡

ROCHESTER, NEW YORK, AND LOS ANGELES, CALIFORNIA

A QUESTIONNAIRE study of 350 nonfatal-accident cases was undertaken to evaluate a short-cut method of history taking. The forms used were designed to reveal possible disorders in an injured patient that might have contributed to the accident. The accident-predisposing factors sought were sensory and neuromuscular disorders. Although emotional factors in accident causation were recognized as important, they were not considered apart from impaired physiology in this study because their importance is already well established.

Scope of the Problem

The type of accident-predisposing disorder that the questionnaires were designed to disclose is exemplified by a patient who usually left his car at home for his family to use, taking a bus to work, and who found himself frequently drowsing on the bus and several mornings in succession passed his stop and was late to work; in danger of losing his job he decided to drive his car. He dozed at the wheel as he had dozed on the bus, crashed into a telephone pole and was badly injured. After he left the hospital he went to his private physician and described what had happened to him. The doctor found hypopituitarism, which was controlled by proper medication, and the patient was no longer an unsafe driver.

This investigation developed from the conviction that an important key to the solution of the problem of the baffling accident will be found in the medical offices of health bureaus and in the offices of private physicians interested in preventive medicine as it applies to accident control. Such physicians would not be content merely to treat an injury successfully. They would seek in addition a possible cause of each patient's accident susceptibility, and through therapy or education, or both, either remove or attenuate the

*Presented in part at the Second Highway Safety Research Correlation Conference on Health, Medical and Drug Factors in Highway Safety, National Research Council, Washington, D. C. April 5-6, 1954.

Supported by a grant from the Division of Pharmacology and Toxicology, University of Rochester School of Medicine and Dentistry.

Study performed in the Department of Radiology, St. Joseph's Mercy Hospital, Ann Arbor, Michigan.

†Research assistant, Division of Pharmacology and Toxicology, University of Rochester School of Medicine and Dentistry.

‡Instructor in radiology, University of California at Los Angeles Medical School.

cause. The hope underlying the study has been that such thorough diagnostic procedures might eventually be carried out with all patients and that a routine of "accident immunization" through diagnosis, therapy and education would eventually be established universally.

Accidents present a problem in preventive medical practice today comparable to that of infectious-disease control at the turn of this century, when universal cleanliness through education and law enforcement was the prophylactic goal. But epidemics continued to ravage the most immaculate communities until it was recognized that the cause of the infectious diseases could be found within the individual patient and that individual immunization was necessary if the epidemics were to be brought under control. Unfortunately, an accident cannot be studied under a microscope. The empirical methods of medical research, which have produced such brilliant results during the last fifty years, do not work in the search for the human factors in accident causation. Perhaps the fact that no new medical technics are necessary in dealing with an accident-liable person has been a deterrent to a widespread search for the insidious factors that may be helping to bring rates from accident disability and death up into epidemic heights on public-health charts. Only searching history-taking procedures seem necessary, with a shift of focus in general practice from the large and spectacular to the small and hidden. Obvious disabilities and other pathologic conditions that ordinarily disturb a patient and bring him to the attention of his physician do not seem to increase accident-susceptibility.[1] It is the subclinical disorder of which a person is not aware that tends to make that person accident liable.

Ideally, the patient who comes to a physician for treatment of an injury should be carefully interrogated about possible disorders that might have contributed to the accident. But, usually, the attending physician is too preoccupied with treatment of the injury to have time for such lengthy procedures. Furthermore, the patient, together with accompanying relatives or friends, is apt to be in such an excited state that an accurate history of accident-predisposing factors is difficult to obtain.

Method

To study a means of bridging the gap between the physician's lack of time and the diagnostic need of the accident-liable patient, the accident questionnaire was devised. The Cornell Medical Index Health Questionnaire was used as a model. That form is composed of about a hundred questions pertaining to health, very simply worded, which a patient can answer by circling "yes" or "no." It has been used successfully in the New York Medical Center and not only saves staff time but often provides information that does not appear during personal history-taking interviews.[2]

The accident questionnaire was set up in much the same form as the Cornell Medical Index, except that all the questions were contrived to find hidden disorders that might cause accidents. The questions were worded as follows:

"Do you frequently forget what you are doing or saying for a few seconds?"

"Do you sometimes fall asleep, or become very sleepy, even when you have had enough rest and should feel wide awake?"

"Can you see out of one eye better than the other?"

"Do you find it hard to hear things that other people seem to hear easily?"

"Does your knee or ankle 'give way'?"

"Does the heat make you 'jittery' when you work in it for a long time?"

"Do you have hay fever or any other allergy?"

"Do you ever take any of the new anti-cold tablets?"

"Are you often 'all thumbs' when you handle objects?"

Space was included at the end for a brief description of the accident that brought the patient to the physician for treatment and for a brief summary of previous hospitalizations and accidents.

The questionnaires were filled out voluntarily during a period of four months by 350 patients who were victims of accidents. There was no selection of cases because of type of accident, age or sex. Most patients were able to fill out the form in ten to twenty minutes. Evaluation of the answers of each patient required two or three minutes of the physician's time.

Several ways of getting patients to fill out the forms were utilized. It was found that a patient was much more interested in the questionnaire after the excitement of the accident had worn off, as when he returned for a follow-up x-ray examination, suture removal or change of dressing, or on the second or third hospital day if the patient was admitted to the hospital. The filling out of the forms in the emergency department was generally unsatisfactory, not only because of the excited state of the patients but also because of lack of time on the part of the nursing and medical staff. However, patients with minor injuries were given the forms to fill out after their injuries had been treated. A convenient time was during the wait for the results of a tetanus-antitoxin intradermal sensitivity test. Most orthopedic patients were asked to fill out forms in the x-ray department while their films were being processed. When the pain was severe the patient was given the form to fill out on return for follow-up x-ray study. Relatives or friends filled out forms for badly injured patients and for young children.

Results

Many difficulties were encountered, not only in getting the patients or relatives to fill out the forms

but also in getting questions answered accurately. Immediate treatment of the injury is a patient's chief concern, together with anxiety over possible complications: disability, work loss and so forth. In such a state he cannot be expected to be interested in a questionnaire procedure, no matter how conscientious he may be. Relatives and friends are usually in a similar state of mind. However, only 14 patients, less than 5 per cent of the total number approached in the study, refused to co-operate. Here, two major deterring factors were observed: some of the patients involved in automobile accidents were suspicious that their answers might be used against them in case of law suit; and some of those injured at work were fearful that their answers might jeopardize their job or their compensation benefits.

Many accident-predisposing disorders were indicated by patients in their answers, but there was no follow-up study by a physician to determine if the suggested disorders were actually causative factors in each particular accident. The purpose of this study was solely to determine whether or not it was possible to obtain information from a patient about accident-predisposing factors by a questionnaire method, requiring only a minimum of time and effort on the part of the attending physician.

A brief analysis of the answers, though of little statistical value, is given because of the interesting questions raised:

Thirty-eight per cent reported being hospitalized before for accidents, some several times. Accident repeaters, as a group, are recognized; why do they have repeated accidents?

Thirty-three per cent reported chronic or episodic lack of co-ordination. Many hidden disorders could have been indicated here, the symptoms of which are dizziness, inebriation, muscular weakness, tremors, unsteady gait, vertigo, lassitude and so forth. Inhalation of the fumes of certain chemicals can produce similar symptoms. Medications such as barbiturates, bromides, antihistaminics, digitalis and atropine have accident-predisposing side effects in some patients.

Twenty-six per cent reported repeated falls, occurring chronically or episodically. Physiotherapists now look for a history of recent infection, which might have been poliomyelitis, when a patient is seen who has suddenly begun to fall upstairs as well as down. A foot drop can prevent the toe of a foot from making its customary lift over the edge of a stair tread, and a fall results. A crack in a walk or a rug can catch such a toe. Does a slightly weakened peroneus muscle group occasionally lower the foot so that it catches under a brake or clutch pedal at a hazardous moment in traffic? It is known that many people suffer a subclinical attack of poliomyelitis of which they are not aware. Does this have an effect on the traffic-accident rate?

Forty-five per cent reported visual defects. Nicotine intoxication can cause diminished visual acuity, and the inability to distinguish red. It is usually associated with cigar smoking and tobacco chewing. However, the use of alcohol, especially when it is associated with a vitamin deficiency, can increase the effects of nicotine intoxication until it becomes suddenly acute. Is there a correlation between this type of intoxication and traffic accidents?

Twenty-four per cent reported hearing limitations. As early as 1913 Munsterberg[3] pointed out that a ship captain who heard well in only one ear was unsafe for his work, because he could not judge from which side a ship blowing a fog horn was approaching. Does this concept have any bearing on the high accident rate among elderly pedestrians? Are some of these victims deaf in one ear, hearing cars apparently approaching from the wrong direction?

Twenty-seven per cent reported symptoms of possible slight petit-mal seizures; 22 per cent reported symptoms of possible psychomotor epileptic seizures.

Twenty-one per cent reported severe headaches of varying frequency.

Twenty-eight per cent reported having at some time received severe blows on the head; 21 per cent of these reported having been knocked unconscious.

Fifteen per cent reported taking antihistamine tablets. Two patients reported an increase in minor accidents after taking thyroid tablets.

Discussion

This preliminary study showed that much more work is needed on the questionnaire before it can provide diagnostic material that a physician would want to use in caring for an accident-liable patient. But even in its first experimental form the method proved feasible for obtaining, quickly and easily, information about accident-predisposing factors.

Undoubtedly, it would be far better if such disorders could be discovered before a patient had a serious accident. One could accomplish this by distributing a similar type of questionnaire to all patients who visit their doctors, regardless of their symptoms. The forms could be filled out while the patients waited for their appointments in the waiting room. This would eliminate the emotional factors concomitant with injuries. More important, such a routine might lead to the prevention of many serious accidents.

The philosophy underlying this study is perhaps more important than the study itself. The precept, "a miss is as good as a mile," should be kept in mind in preventive control of accidents. There may be only a hairsbreadth of space or a split second of time between a missed accident and a fatal outcome. In a slight deviation from usual behavior the narrow margin between a safe and an unsafe action can be removed.

Every healthy adult has built up conditioned mechanisms of self-preservation. It is impossible in this complex civilization to think constantly of all the possible hazards that should be avoided. The causal variables surrounding every accident are often multitudinous and cannot be wholly anticipated. Therefore, modern man must rely on his conditioned responses to protect himself without too much concentration on his part.

Any disorder within a patient, chronic or episodic, that tends to disturb these protective mechanisms can contribute to accident susceptibility. When such a disturbance is combined with an opportune environmental hazard an accident is likely. Weinerman[4] gives this summation of the accident problem: "Proneness to accident is at once an attribute of the disturbed personality, impaired physiology, and unsafe conditions of environment. Successful prevention must recognize the total ecologic complex." The "impaired physiology" of this triad is the responsibility of the medical profession.

Summary

A study of the questionnaire method for obtaining information from patients about accident-predisposing factors was done. Three hundred and fifty patients with accidental injuries voluntarily filled out questionnaire forms. Although many difficulties were encountered, the method was found feasible.

References

1. Dunbar, F. *Psychosomatic Diagnosis.* 183 pp. New York: Hoeber, 1943.
2. Brodman, K., et al. Cornell Medical Index: adjunct to medical interview. *J.A.M.A.* 6:140, 1949.
3. Munsterberg, H. *Psychology and Industrial Efficiency.* 95 pp. Boston: Houghton Mifflin, 1913.
4. Weinerman, E. R. Accident-proneness: critique. *Am. J. Pub. Health* 39:1530, 1949.

MEDICAL PROGRESS

CARCINOMA IN SITU (Concluded)*

ROBERT H. FENNELL, JR., M.D.,† AND BENJAMIN CASTLEMAN, M.D.‡

BOSTON

Skin and Other Nonglandular Surfaces

Skin

Since the skin is the area most accessible to inspection, it is natural that lesions suspected of being precancerous should be carefully watched for long periods. This was the procedure when Bowen[65] (1912), in his original description of "precancerous dermatosis," described its evolution into invasive cancer. This evolution, however, was slow and in 1 of his cases had not occurred in nineteen years. In Bowen's disease all gradations of intermixture of apparently benign and malignant cells may be found, but the malignant cells are limited to the epithelial layers. It was shown that the process could eventuate in cancer, and metastases were demonstrated in 1 case reported by Darier and cited in Bowen's[66] second paper. Stout's[67] review of Bowen's disease in 1939 revealed that only 2 or 3 per cent of skin lesions showed invasion and that in only rare cases did metastases occur. Finnerud and Duncan[68] reported a case of Bowen's disease that was present thirty years before a squamous-cell carcinoma was found in a regional lymph node.

Another skin lesion that is associated with varying degrees of cellular atypism is arsenical keratosis. Resemblance to Bowen's disease has led some writers[69] to attribute Bowen's disease to arsenic ingestion. This is generally denied,[70] but skin cancers do develop in arsenical keratosis. Neubauer's[71] review included 81 cases of which 44 were of squamous-cell, 24 of basal-cell, 1 of mixed and 10 of both types. One case was microscopically exactly identified as Bowen's disease. Sommers and McManus[72] also encountered Bowen's disease among their cases.

The erythroplasia of Queyrat is considered by some[73,74] as Bowen's disease of the mucous membranes, but this seems to be oversimplification of a difficult problem. The histologic descriptions and illustrations of reported cases are not those of Bowen's disease, and the response of some cases to topical therapy raises doubt about the nature of the process. In the review by McDaniel and Mason,[75] which included 19 cases in American literature, there was histologic evidence of malignant degeneration in 5. Dixon and Moore[75] did not consider the lesion as true carcinoma in situ, for the epithelial cells do not show the anaplasia and disorganization characteristic of neoplasm.

Extramammary Paget's disease is, like Paget's disease of the nipple, an intraepidermal metastasis from an apocrine-gland carcinoma, the breast being a specialized apocrine gland. In Weiner's[76] review all the cases were in the axilla or anogenital region, where apocrine glands are located. It is an uncommon disease; Parsons and Lohlein[77] described in 1943 what

*From the departments of Pathology, Harvard Medical School and the Massachusetts General Hospital.

†Formerly, instructor in pathology, Harvard Medical School, and assistant pathologist, Massachusetts General Hospital.

‡Clinical professor of pathology, Harvard Medical School; chief, Department of Pathology, Massachusetts General Hospital.

they thought was the sixteenth case. Confirmatory evidence of its metastatic nature is given by cases of a known primary cancer other than in the skin simulating Paget's disease.[78,79]

Senile keratosis often shows some cytologic atypicality; indeed, atypicality may be considered a prerequisite to its diagnosis. In our experience squamous-cell carcinomas that appear to arise from senile keratosis do so by becoming invasive and then dedifferentiating. They do not usually pass through a recognizable stage of carcinoma in situ.

Vulva

Knight's[80] review of Bowen's disease of the vulva disclosed 26 cases, and he added 6 from Sloane Hospital. Jeffcoate, Davie and Harrison[81] described intraepidermal carcinoma as a dull-red, raw area, with a clearly defined circinate or serpiginous outline, perhaps slightly raised, and with a moist or partially encrusted surface. Pain and pruritus were the usual symptoms. One of their 2 patients succumbed to the disease. Extension to the mucous membrane was thought to increase the likelihood of invasion. Radiation was considered of questionable therapeutic value.

In a review of 112 cases of carcinoma of the vulva Gardiner et al.[82] found 2 intraepithelial carcinomas. Six more were found at the margin of invasive cancer. A seven-year and an eleven-year interval existed between the diagnosis of intraepithelial carcinoma and the detection of an invasive lesion. The intraepithelial carcinoma described was different from true Bowen's disease. In a review of 32 cases of leukoplakia, these authors found no intraepithelial carcinoma. Arneson, in discussing the paper, stated that he had found 3 carcinomas in situ in 40 carcinomas of the vulva; 1 case was extensive. He noted that the change may extend into the vagina.

Anus

Squamous-cell carcinoma in situ of the anus has been described as a reddened area[83] or as an anal tab.[84] Treatment by total excision or by radium has been successful.

Mouth and Pharynx

Two reviews of carcinoma in situ of the upper respiratory and alimentary tracts named the lesion as "Bowen's" disease.[85,86] The few reported cases in the mouth have clinically resembled leukoplakia, and the diagnosis was made by microscopical study. One of the cases described by Stout[87] began as a red spot in the floor of the mouth, and was treated by radium after the biopsy showed "Bowen's disease." Three years later a lymph node was palpable, and 2 of 13 dissected lymph nodes contained tumor. No invasion was demonstrated in multiple sections of the excised mouth lesion though it was not serially sectioned. We agree with Stout that "one cannot doubt that penetration must have occurred, for otherwise metastases would be inconceivable, but it is also evident that this must be only microscopic in degree." He recommended complete surgical excision as the treatment of choice. Isolated cases of carcinoma in situ of the tongue,[87,88] nares[87,89] and pharynx[89] have been reported.

Larynx

In a series of 312 epitheliomas of the larynx reported by Altman, Guisberg and Stout[90] 29 (9.3 per cent) showed only intraepithelial carcinoma. In 9 cases invasion was microscopic and very limited, and in 10 carcinoma in situ was at the margin of invasive cancer. Extension of the growth into ducts occurred in 45 per cent of the cases and was not considered evidence of invasion. The great majority of the tumors arose from the vocal cords, usually were anterior and appeared as gray, white or reddish thickening. The authors advocated more conservative therapy for this lesion than for invasive cancer. Stewart[91] reported a case with a seven-year history, and Clerf[92] 1 with an eleven-year history; in each, after clinical cancer developed, a review of the initial biopsy showed carcinoma in situ.

Lung

Most of the descriptions of carcinoma in situ of the bronchi are of those bordering an invasive lesion.[93-98] Most authors emphasize the fact that intraepithelial carcinoma in a biopsy usually indicates that invasive cancer is present elsewhere. Multiple foci of carcinoma in situ may be found, and, in the discussion of the report by McGrath et al.,[97] McDonald expressed the idea that carcinoma in situ proximal to invasive lesions may be the explanation for many stump recurrences.

There have been, however, a few single case reports of carcinoma in situ of the bronchial mucosa in the absence of an invasive lesion nearby. Urnicker and Storey[99] described a patient with cough, sputum and hemoptysis and a mass on x-ray examination. Biopsy showed a noninfiltrating epidermoid carcinoma; no invasion was found in the resected specimen. The lesion seen on the x-ray film was a fibrocaseous nodule. They interpreted the carcinoma in situ as having developed from squamous-cell metaplasia. The case described by Papanicolaou and Koprowska[100] was detected by cytologic study; when the lung was studied at autopsy it was free of invasion, death resulting from edema and pneumonia. This case emphasizes the quandary facing the physician whose patient has tumor cells in the sputum without a demonstrable lesion roentgenologically or bronchoscopically. Weirman et al.[93] described 1 case with carcinoma in situ only, in addition to 4 others with invasive areas nearby. They emphasized loss of normal longitudinal grooves in the areas of carcinoma in situ noted grossly by the bronchoscopist. Others also

noted this, or described a granular area at the site of the carcinoma in situ.

Several authors have reported examples of small tumors, often multiple and usually located peripherally, that have been called early carcinomas. It is difficult to determine from the photographs whether or not these are examples of benign proliferation as described by Liebow.[101] We have seen similar changes and have considered them as atypical benign epithelial proliferations. Others doubt if these foci represent early bronchogenic carcinoma, and Prior[102] reaffirms their benign nature. The case of multiple minute bronchiolar carcinoma with a metastasis to a bronchial lymph node described by Spain and Parsonnet[103] may be interpreted as being in the group of true carcinoma in situ, with multiple foci of invasion.

Eye

A few cases of carcinoma in situ have been recognized in the corneas and conjunctivas. McGavic[104] described it as "slightly elevated, diffuse, sometimes multiple, highly vascularized patches of reddish-gray, gelatinous tissue" and discussed the differential diagnosis. Histologically, the lesion in his 5 cases was described as having the features of Bowen's disease. Complete surgical excision was recommended. The disease may be difficult to eradicate.[105] Radiotherapy was the method of choice in several cases[106,107]; others treated the lesion by excision.[108,109] Ash and Wilder[110] recognized carcinoma in situ in a "number of instances" among 93 epithelial tumors arising at or near the limbus.

Gall Bladder

Tobak and McNeer[111] reported 4 cases of papillomas in the gall bladder, in 3 of which carcinoma in situ was found. The specimens appear to be good examples from the photographs furnished. The authors considered gall-bladder papillomas very prone to become malignant.

Urinary System

A single case of carcinoma in situ of the kidney was detected by cytologic study of urine.[112] Hematuria developed, and urine from the right kidney contained tumor cells. A pyelogram was normal, but the excised kidney showed carcinoma in situ in sections of the calyxes.

Melicow and Hollowell[113] presented 30 cases of carcinoma in situ of the urinary system — 1 of the renal pelvis, 2 of the ureter, 17 of the bladder, 5 of the urethra and 5 of the penis. Many of the lesions were at the margin of invasive cancer. In their Case 28 reoperation was performed three weeks after a biopsy had revealed "Bowen's disease," and yet the excised organ and lymph nodes already showed a diffuse invasion. Nothing but confusion can result from the application of the term "Bowen's disease" to a case in which there must be advanced cancer at the time of biopsy. The report adds little to an understanding of the problem.

Another case of carcinoma in situ detected by the cytologist was of the prostate; this tumor, by intraepithelial extension, involved the urethra and urinary bladder.[114] Invasion was demonstrated in the bladder. The diagnosis of "Paget's disease," as applied to this lesion stretches the meaning according to our concept of the term.

Glandular Surfaces

Gastrointestinal Tract

In any discussion of carcinoma in situ involving glandular structures, one immediately thinks in terms of the changes occurring in polypoid tumors, especially of the gastrointestinal tract. So much has been written about polyps of the colon and their tendency to malignant change that only a brief statement is made here about the role of carcinoma in situ in these cases. Adenomatous polyps, or so-called adenomas, of the gastrointestinal tract often show marked epithelial anaplasia, especially on their surfaces. At times these cells cannot be differentiated from true carcinomatous cells and then the lesion may rightfully be called carcinoma in situ, since there is no evidence of penetration of the muscularis mucosa. If the lesion is not sessile but truly polypoid with a definite stalk, not a man-made stalk produced by traction on the lesion with an instrument, we believe that simple excision without bowel resection is adequate treatment, even if microscopical examination reveals carcinoma in situ.

Nonpolypoid carcinoma in situ of the gastrointestinal tract is relatively uncommon; in the intestine it is extremely rare. In the stomach the nonpolypoid lesion tends to ulcerate, and cytologic smears of the gastric washings have been a factor in detecting 6 cases in our laboratory. Others have also had similar experiences.[115] Mallory[116] presented an excellent and thorough discussion of this entity. His photographs and descriptions emphasized the cytologic changes, with preservation of the glands of the stomach. Pleomorphism and hyperchromatism of the nuclei, abnormally situated mitoses, loss of polarity and thickening of cell layers were characteristic changes. The lesions were all limited to the mucosa and should not be confused with Stout's[117] "superficial spreading type of carcinoma," which is already invasive and which shows metastases in 39 per cent of cases.

The malignant potentiality was emphasized by Mallory in citing, among other evidence, definite early invasion in 1 case. Geffroy and Jouanneau[118] reported a case in which an ulcer was demonstrated four years before operation. The resected stomach showed carcinoma in situ, and six years later the patient died with cancer of the stomach. In the original surgical specimen no mention was made of

the resection edges, so that it is possible that residual disease slowly led to an invasive carcinoma. Collins and Gall[119] described the frequent appearance of carcinoma in situ at the margins of invasive cancer of the stomach, but they also found independent foci of preinvasive carcinoma.

The photograph and description of a lesion of the stomach in a report by Albot et al.[120] suggests the atypism resulting from regeneration at the margin of an ulcer; this can be confusing and is easily mistaken for carcinoma in situ. Mallory[116] described the abrupt malignant transition from normal, in contrast to the gradual transition of the regenerating epithelium at the edge of a benign peptic ulcer.

In addition to describing the detailed histologic criteria for making a diagnosis of carcinoma in situ of the stomach, Mallory demonstrated the not infrequent occurrence of peptic ulceration of carcinomatous tissue. He continued with the following comment:

> It is logical to assume that this [peptic ulceration of carcinomatous tissue] would be most frequent in the early stages of carcinomatous involvement of the stomach, when secretion is still fairly normal. If peptic ulceration occurred in an area of carcinoma in situ, it would quickly ulcerate through the shallow layer of neoplastic tissue, most of which would be destroyed. Though theoretically the entire tumor might ulcerate away, as Stromeyer has suggested, this seems improbable. However, a deep peptic ulcer might develop with only fragments of persisting tumor about its margins. Such a picture has usually been interpreted as evidence of cancer developing in ulcer, but if carcinoma in situ behaves in the stomach as it does in other organs, the cancer may well have developed before the ulcer. One of the major arguments for the development of carcinoma in ulcer is therefore open to question, if not invalidated.

McCollum and Pund[121] described 16 cases of carcinoma in situ of the appendix that were incidental findings. In 5 of the 16 the carcinomatous epithelium extended throughout the appendix, and in the others it was only a focal change. From the photographs, it is difficult to know if all the lesions were truly carcinoma in situ; some appear to be merely glandular hyperplasia.

Endometrium

Hertig, Sommers and Bengloff[122] reported 64 cases of carcinoma in situ of the endometrium from the Free Hospital for Women in Brookline, Massachusetts. No gross picture is typical. The diagnosis is a microscopical one and interpretation of cytologic changes is important. The hallmark of the carcinoma in situ of the endometrium is the glands composed of large cells, with abundant clear eosinophilic cytoplasm. These are often sharply demarcated from adjacent tissue. Fourteen occurred in polyps. Cancer developed in 6 of the 64 patients, and 3 died. Hysterectomy was successful treatment in 45, in 25 of which the lesion was first recognized in the hysterectomy specimen. Of 5 who had curettage only, the lesion persisted in 2; in 2 it became less suspicious, and in the fifth it showed regression of morphologically typical disease for three years after pregnancy. The developmental life history of carcinoma in situ morphologically was thought to follow a succession of polyps, cystic hyperplasia, adenomatous hyperplasia and anaplasia. The irreversible stage was characterized by the pale eosinophilic glands. The time sequence suggested by the authors is subject to the same criticism as such chronologic relations for cervical carcinomas, with the addition that fewer data on early endometrial cancers are available.

Novak and Rutledge[123] gave a different interpretation of the changes, which from some of their photographs are quite similar to what Hertig et al.[122] called carcinoma in situ, by calling them atypical hyperplasia. The treatment and short follow-up period mentioned by Novak and Rutledge make it impossible to evaluate the growth potential of the lesion shown. Marsubini,[124] cited by Hertig and his associates[122] as describing carcinoma in situ that progressed to invasive cancer, stated that he could not see "changes as stages of transition towards a cancer, along the lines accepted for some lesions of the cervix [so-called intraepithelial cancer]."

TeLinde, Jones and Galvin,[125] in a more recent paper, supported the concept of carcinoma in situ though they did not use the term. They stated that many lesions in their material diagnosed as "atypical hyperplasia," "adenomatous hyperplasia" and so forth were in fact carcinoma. Speert[126] wrote of "the premalignant phase of endometrial carcinoma" and described the atypical hyperplasia found in 11 of 13 cases, but he did not indicate a conviction that such lesions were actually carcinoma in situ.

A consideration of the early form of endometrial carcinoma entails the problem of its relation to hyperplasia and whether the hyperplasia is transformed to carcinoma, or whether the process is neoplasia from its incipiency. Numerous papers have been written on this matter, and there are carefully done studies that contradict each other. Larson,[127] in a critical review of the relation of estrogens to endometrial carcinoma, concluded that there was little proof of an etiologic relation between hyperplasia and carcinoma. We agree that there is only suggestive evidence, and here, as in other studies, review of prior biopsies in patients with cancer weigh the evidence heavily in the direction of carcinoma developing in pre-existing hyperplasia. Many of the lesions called atypical adenomatous hyperplasia of the endometrium may be justly considered as carcinoma in situ. If so, we have no more conclusive evidence pertaining to carcinoma in situ of the endometrium than to that of the cervix, to which the same fundamental question asked by Dunn[82] about transitions from in situ to invasion are not answered.

Breast

The literature contains few references to carcinoma in situ in the breast. Foote and Stewart[128]

described in 1941 a lesion that they called "lobular carcinoma in situ." More recently, Stewart[129] renamed it "noninfiltrating lobular carcinoma." The lesion cannot be recognized clinically or grossly and is an incidental microscopical finding in breast tissue with or without invasive carcinoma. As its name indicates, the cells of a single lobule or group of lobules are large and only slightly atypical but are disorganized. The transition from normal to carcinoma in situ is sharp. Lobular carcinoma in situ is said to be always a disease of multiple foci, indicating the necessity for simple mastectomy; obviously, if infiltration is found, a radical resection is necessary. Stewart mentioned "five-year cures" by wide local incision. Godwin[130] reported a case of breast carcinoma with death occurring two years after radical mastectomy. A review of the biopsy taken twelve years before operation showed lobular carcinoma in situ. He cited the frequency with which the disease may be in the wall of a cyst, and how often it is multicentric in origin. Two similar examples were studied in his laboratory.

The term carcinoma in situ should not be applied to the intraductile papilloma that on occasion shows epithelial atypism because the occurrence of frank intraductile noninfiltrating papillary carcinoma is extremely rare. We agree with Stewart[129] that, "The actual number of papillary lesions that eventually become mammary cancers must necessarily be a very minute fraction. . . ."

Paget's disease of the nipple is an intraductile extension of a breast carcinoma. The lesion may be entirely intraductile — comedocarcinoma — but usually extends outside the ducts. It should not be considered as carcinoma in situ and should be treated as cancer.

Discussion

Carcinoma in situ is a vitally important subject. We should like to know if all carcinomas pass through such a stage, for at that time all should be curable. We should also like to know if all carcinomas in situ, or the lesions so designated, progress inevitably to cancer, and how long this metamorphosis takes. It may be reasonable to assume that all cancers begin as in-situ lesions, but we have no evidence for such an assumption. Fallacies in attempts to prove that this is true in the uterine cervix have been emphasized. In the skin one might expect to find carcinoma in situ, or Bowen's disease, quite commonly if all skin cancers were preceded by this lesion. Actually, Bowen's disease is rare.

The proof that the histologic changes now called carcinoma in situ are actually those of preinvasive cancer is tenuous. The question was dealt with in the discussion of the uterine cervix, which has been studied more with respect to this problem than any other organ. Some cases appear bona fide, but what degree of atypism correlates with the irreversible stage of true cancer has not been established. It is difficult to believe that, with the wide range of epithelial changes called carcinoma in situ in published reports, and in material privately seen by us, all have the ability to become invasive cancer. In the absence of invasion, interpretation of cytologic changes by the individual pathologist forms the basis for the diagnosis. It is doubtful if each pathologist has made a follow-up study of enough patients to determine the fine correlation of structure and function that is needed.

The pathologist has had little opportunity to learn, for the clinician usually removes the tissue or organ in question the moment the pathologist expresses any doubt that the lesion is completely benign. Unwillingness to jeopardize the patient is commendable, but much can be learned with minimal danger to the patient, and the few basic facts about this problem have been obtained by close co-operation among patient, clinician and pathologist.

It is to animal experimentation that one turns for information when human experimentation cannot be utilized. Conclusive data are few, as Steiner[131] pointed out clearly, although more recently 2 examples of lesions of the cervix resembling human carcinoma in situ were reported.[132,133] Ritchie[134] stated that in experimental production of thousands of skin tumors in mice no carcinoma in situ was encountered. Murphy[135] produced squamous-cell carcinomas in mice but did not encounter carcinoma in situ although a single papillary lesion bore some resemblance to it. No experimental evidence exists that all cancer passes through an in-situ stage, and unless the lesion can be regularly produced a study of the growth potential of a given degree of atypism cannot be made.

Until more is known of carcinoma in situ the treatment now widely used of simple excision of the diseased tissue seems reasonable. Radical methods seem unjustified. As the lesion exists frequently in the cervix of young women, a plea is made to consider the reproductive capabilities of these patients and the low-grade nature of the process called carcinoma in situ.

Conclusions

Several features characterize carcinoma in situ as it has been found in different locations. It is either not visible grossly or has no characteristic gross appearance. On microscopical study it is occasionally seen at the margin of invasive cancer though by definition, of course, it is not invasive. Since invasion must be absent the diagnosis is based solely on an interpretation of cytologic changes and the arrangement of the cells.

Carcinoma in situ sometimes has multiple sites of origin, and it may extend to involve a large area without becoming invasive. In many of the locations the lesion in situ has been shown to progress to an

invasive cancer, but the interval until cancer is manifest is measured in years or decades.

Because most of the cases have been found by retrospective studies after cancer had developed, little information is available regarding the possible reversibility of the lesion now called carcinoma in situ. Much more information is needed about the histologic details and the correlation of growth potential with that of structure. Until more is known, conservative surgical excision seems to be the treatment of choice.

References

65. Bowen, J. T. Precancerous dermatoses: study of two cases of chronic atypical epithelial proliferation. *J. Cutaneous Dis.* **30**: 241-255, 1912.
66. *Idem.* Precancerous dermatoses: sixth case of type recently described. *J. Cutaneous Dis.* **33**:787-802, 1915.
67. Stout, A. P. Malignant manifestations of Bowen's disease. *New York State J. Med.* **39**:801-809, 1939.
68. Finnerud, C. W., and Duncan, E. T. Bowen's precancerous dermatosis, Bowen's disease. *M. Clin. North America* **33**:125-134, 1949.
69. Anderson, H. P. Bowen's precancerous dermatosis and multiple benign superficial epitheliomas: evidence of arsenic as etiologic agent. *Arch. Dermat. & Syph.* **26**:1052-1064, 1932.
70. Montgomery, H. Arsenic as etiologic agent in certain types of epithelioma. *Arch. Dermat. & Syph.* **32**:218-236, 1935.
71. Neubauer, O. Arsenical cancer: review. *Brit. J. Cancer* **1**:192-251, 1947.
72. Sommers, S. C., and McManus, R. G. Multiple arsenical cancers of skin and internal organs. *Cancer* **6**:347-359, 1953.
73. McDaniel, W. E., and Mason, L. M. Malignant dyskeratosis, erythroplasia of Queyrat type. *Arch. Dermat. & Syph.* **68**:419-424, 1949.
74. Lever, W. F. *Histopathology of the Skin.* 449 pp. Philadelphia: Lippincott, 1949. P. 290.
75. Dixon, F. J., and Moore, R. A. Tumors of male sex organs. In *Atlas of Tumor Pathology*, United States Armed Forces Institute of Pathology. Washington, D. C., 1952.
76. Weiner, H. A. Paget's disease of skin and its relation to carcinoma of apocrine sweat glands. *Am. J. Cancer* **31**:373-403, 1937.
77. Parsons, L., and Lohlein, H. E. Extramammary Paget's disease. *Arch. Path.* **36**:424-427, 1943.
78. Pinkus, H., and Gould, S. E. Extramammary Paget's disease and intraepithelial carcinoma. *Arch. Dermat. & Syph.* **39**:479-502, 1939.
79. Docherty, M.D., and Pratt, J. H. Extramammary Paget's disease: report of four cases in which certain features of histogenesis were exhibited. *Cancer* **5**:1161-1169, 1952.
80. Knight, R. Bowen's disease of vulva. *Am. J. Obst. & Gynec.* **46**:514-524, 1943.
81. Jeffcoate, T. N. A., Davie, T. B., and Harrison, C. V. Intraepidermal carcinoma (Bowen's disease) of vulva: report on two cases. *J. Obst. & Gynaec. Brit. Emp.* **51**:377-385, 1944.
82. Gardiner, S. H., Stout, F. E., Arbogast, J. L., and Huber, C. P. Intraepithelial cancer of vulva. *Am. J. Obst. & Gynec.* **65**:539-548, 1953.
83. Vickers, P. M., Jackman, R. J., and McDonald, J. R. Anal carcinoma in situ: report of three cases. *South. Surgeon* **8**:503-507, 1939.
84. Freund, M. H. Bowen's disease of anus and anal region. *Tr. Am. Proct. Soc.* **42**:149-152, 1942.
85. Gorlin, J. R. Bowen's disease of mucous membrane of mouth: review of literature and presentation of six cases. *Oral Surg.* **3**: 35-51, 1950.
86. Brighton, G. R., and Altman, F. Bowen's disease and superficial mucosal epithelioma of upper respiratory and alimentary tracts. *Arch. Otolaryng.* **36**:354-371, 1942.
87. Cipollaro, A. C., and Foster, P. D. Bowen's precancerous dermatosis of mucous membrane. *New York State J. Med.* **40**:264-275, 1940.
88. Slaughter, D. P., Southwick, H. W., and Smejkal, W. "Field cancerization" in oral stratified squamous epithelium: clinical implications of multicentric origin. *Cancer* **6**:963-968, 1953.
89. Bullock, W. K., and Snyder, E. N. Carcinoma in situ occurring in pharyngeal diverticulum. *Cancer* **5**:737-739, 1952.
90. Altman, F., Guisberg, I., and Stout, A. P. Intraepithelial carcinoma (cancer in situ) of larynx. *Arch. Otolaryng.* **36**:121-133, 1952.
91. Stewart, F. W. Experiences in spontaneous regression of neoplastic disease in man. *Texas Rep. Biol. & Med.* **10**:239-253, 1952.
92. Clerf, L. H. Cancer of larynx: report of unusual case. *Tr. Am. Laryng. A.* **66**:167-170, 1944.
93. Weirman, W. H., McDonald, J. R., and Clagett, O. T. Occult carcinoma of major bronchi. *Surgery* **35**:335-345, 1954.
94. Williams, M. J. Extensive carcinoma in situ in bronchial mucosa: associated with two invasive bronchogenic carcinomas. *Cancer* **5**:740-747, 1952.
95. Carlisle, J. C., McDonald, J. R., and Harrington, S. W. Bronchogenic squamous cell carcinoma. *J. Thoracic Surg.* **22**:74-82, 1951.
96. Nielsen, K. O. Observations on metaplasia of bronchial epithelium and its relation to carcinoma of lung; pathoanatomical and experimental research. *Acta path. et microbiol. Scandinav.* **28** (Supp. 80):1-80, 1949.
97. McGrath, E. J., Gall, E. A., and Kessler, D. P. Bronchogenic carcinoma: product of multiple sites of origin. *J. Thoracic Surg.* **24**:271-283, 1952.
98. Black, H., and Ackerman, L. V. Importance of epidermoid carcinoma in situ in histogenesis of carcinoma of lung. *Ann. Surg.* **136**:44-55, 1952.
99. Urnicker, W., and Storey, C. Bronchogenic carcinoma in situ: report of case with positive biopsy, cytological examination and lobectomy. *Cancer* **5**:369-374, 1952.
100. Papanicolaou, G. N., and Koprowska, I. Carcinoma in situ of right lower lobe bronchus: case report. *Cancer* **4**:141-146, 1951.
101. Liebow, A. Tumors of lower respiratory tract. In *Atlas of Tumor Pathology*. United States Armed Forces Institute of Pathology. Washington, D. C., 1952.
102. Prior, J. T. Minute peripheral pulmonary tumors: observations on their histogenesis. *Am. J. Path.* **29**:705-712, 1953.
103. Spain, D. M., and Parsonnet, V. Multiple origin of minute bronchiolargenic carcinomas: report of case. *Cancer* **4**:277-285, 1951.
104. McGavic, J. Intraepithelial epithelioma of cornea and conjunctiva (Bowen's disease). *Am. J. Ophth.* **25**:167-176, 1942.
105. Khanolkar, V. R. Bowen's disease of conjunctiva. *Am. J. Ophth.* **35**:515-519, 1946.
106. Esterman, B., Laval, J., and Okrainetz, C. Intraepithelial epithelioma of cornea and conjunctiva (Bowen's disease). *Am. J. Ophth.* **30**:1537-1540, 1947.
107. Francois, J., Kluyskens, J., and Rabaey, M. Intraepithelial epithelioma of conjunctiva and cornea (Bowen's disease) healed by contact radiotherapy. *Brit. J. Ophth.* **34**:360-364, 1950.
108. Weskamp, C. Bowen's disease of cornea. *Arch. Ophth.* **31**: 310-315, 1944.
109. Wise, G. Case of Bowen's disease of cornea. *Am. J. Ophth.* **28**: 167-171, 1945.
110. Ash, J. E., and Wilder, H. C. Epithelial tumors of limbus. *Tr. Am. Acad. Ophth.* **46**:215-222, 1942.
111. Tobak, E. J., and McNeer, G. Papilloma of gallbladder with in-situ carcinoma. *Surgery* **34**:57-71, 1953.
112. Foot, N. C., and Papanicolaou, G. N. Early renal carcinoma in situ. *J. A. M. A.* **139**:356-358, 1949.
113. Melicow, M. M., and Hollowell, J. W. Intra-urothelial cancer: carcinoma in situ, Bowen's disease of urinary system: discussion of thirty cases. *J. Urol.* **60**:763-772, 1952.
114. Ortega, L. G., Whitmore, W. F., and Murphy, A. I. In-situ carcinoma of prostate with intraepithelial extension into urethra and bladder: Paget's disease of urethra and bladder. *Cancer* **6**: 898-923, 1953.
115. Traut, H. F., Rosenthal, M., and Harrison, J. T. Evaluation of cytologic diagnosis of gastric cancer. *Surg., Gynec. & Obst.* **95**: 709-716, 1952.
116. Mallory, T. B. Carcinoma in situ of stomach and its bearing on histogenesis of malignant ulcers. *Arch. Path.* **30**:348-362, 1940.
117. Stout, A. P. Superficial spreading type of carcinoma of stomach. *Arch. Surg.* **60**:807-822, 1943.
118. Geffroy, M., and Jouanneau, P. Deceptive evolution of cancer "in situ" of stomach. *Arch. mal. app. digest.* **40**:76-82, 1951.
119. Collins, W. T., and Gall, E. A. Gastric carcinoma: multicentric lesion. *Cancer* **5**:62-72, 1952.
120. Albot, G., Bosset, J., Bertrand, I., and Parturier-Lannegrace, M. Primary cancer "in situ," strictly localized in mucous membrane: early radioclinical and gastroscopic diagnosis. *Presse méd.* **50**:711-712, 1942.
121. McCollum, W., and Pund, E. R. Preinvasive adenocarcinoma of appendix: report of sixteen cases. *Cancer* **4**:261-264, 1951.
122. Hertig, A. T., Sommers, S. C., and Bengloff, H. Genesis of endometrial carcinoma. III. Carcinoma in situ. *Cancer* **5**:964-971, 1949.
123. Novak, E., and Rutledge, F. Atypical endometrial hyperplasia simulating adenocarcinoma. *Am. J. Obst. & Gynec.* **55**:46-63, 1948.
124. Marrubini, G. Doubtful malignant changes in endometrial epithelium: report on 60 cases from Radiumhemmet. *Acta. radiol.* **31**:65-84, 1949.
125. TeLinde, R. W., Jones, H. W., and Galvin, C. A. What are earliest endometrial changes to justify diagnosis of endometrial cancer? *Am. J. Obst. & Gynec.* **66**:953-965, 1953.
126. Hertig, A. T. Malignant phase of endometrial carcinoma. *Cancer* **5**:927-944, 1952.
127. Larson, J. A. Estrogens and endometrial carcinoma. *Obst. & Gynec.* **3**:551-572, 1954.
128. Foote, F. W., and Stewart, F. W. Lobular carcinoma in situ: rare forerunner of mammary cancer. *Am. J. Path.* **17**:491-495, 1941.
129. Stewart, F. W. Tumors of breast. In *Atlas of Tumor Pathology*. United States Armed Forces Institute of Pathology. Washington, D. C., 1950.
130. Godwin, J. T. Chronology of lobular carcinoma of breast. *Cancer* **5**:259-266, 1952.
131. Steiner, P. Human significance of experimental carcinogenesis. *Arch. Path.* **55**:227-244, 1952.
132. von Haam, E., and Scarpelli, D.G. Comparative cytological and histological study of experimental carcinoma of cervix. Presented at the annual meeting of the Inter-Society Cytology Council, Boston, November 12 and 13, 1954.
133. Pratt-Thomas, H. R. Carcinogenic effect of human smegma: experimental study: preliminary report. Presented at the symposium on cancer of the uterus of the American Cancer Society, New York City, October 18 and 19, 1954.
134. Ritchie, A. C. Personal communication.
135. Murphy, E. D. Studies on carcinogen-induced carcinoma of cervix in mice. *Am. J. Path.* **29**:608, 1953.

MEDICAL INTELLIGENCE

TREATMENT OF AGRANULOCYTOSIS DURING PREGNANCY WITH ANTIBIOTICS, ACTH AND CORTISONE*

Report of a Case

OLIVER H. DURAND, M.D.,† CURTIS M. FLORY, M.D.,‡ AND WOODHULL S. HALL, M.D.§

BENNINGTON, VERMONT

SEVEN cases of agranulocytosis treated with ACTH or cortisone have been reported in the literature.[1-4] Of these patients 6 recovered, and 1 died. The report of an additional case so treated follows.

CASE REPORT

A 32-year-old housewife was admitted to the hospital with an illness of 4 days' duration characterized by low fever, increasing pharyngitis and severe malaise.

On physical examination the throat was severely inflamed, with many scattered patches of adherent membrane. She was extremely hoarse and coughing, and there was respiratory stridor. Throat smear and culture showed only a nondescript mixture of *Streptococcus viridans*, nonhemolytic streptococcus and yeast cells.

Examination of the blood showed a red-cell count of 3,800,000, with a hemoglobin of 11.6 gm. per 100 cc., and a white-cell count of 1600, with 100 per cent lymphocytes and 350,000 platelets.

It was learned that for several months the patient had been taking Amytal Sodium, acetylsalicylic acid, a triple bromide and an analgesic tablet containing 0.15 gm. of aminopyrine, 0.015 gm. of phenobarbital and 0.015 gm. of extract of hyoscyamus.

A diagnosis of agranulocytosis due to drug reaction, probably aminopyrine, was made. The initial therapy consisted of supportive measures, whole-blood transfusions and antibiotics (at first a mixture of penicillin and dihydrostreptomycin). The patient had been under treatment with oxytetracycline for 3 days before admission, without symptomatic improvement. The reports of 7 cases in the literature having been encouraging, she was given ACTH at the rate of 20 mg. every 6 hours. In the first 5 hospital days there was no change in her general condition. The throat if anything grew worse, and the daily blood counts remained the same. On the 5th hospital day she seemed definitely worse and much weaker. At this time the ACTH was discontinued, and cortisone substituted in a dose of 50 mg. every 6 hours. On the afternoon of the 6th hospital day, the white-cell count was 1400, with 96 per cent lymphocytes and 4 per cent monocytes. On the evening of the 6th day she had a severe shaking chill, and the temperature rose to 105°F. by rectum. There was no other change in her physical condition. A blood culture taken at that time was later reported as sterile. Meanwhile oxytetracycline was added to the antibiotics.

On the morning of the 7th hospital day, the white-cell count had risen to 3100, with 49 promyelocytes, 10 neutrophilic myelocytes, 3 stab forms, 1 segmented neutrophil, 1 eosinophil, 122 lymphocytes, 2 monocytes, 4 nucleated red cells and 8 megaloblasts out of 200 cells counted. In the afternoon of the same day the white-cell count rose to 7900, with 39 myelocytes, 1 stab form, 1 segmented form, 56 lymphocytes, 1 monocyte and 2 erythroblasts out of 100 cells. On the 10th hospital day the count had risen to 29,300, with many immature forms still present. With the reappearance of granulocytes in the blood, the patient's clinical condition improved greatly and rapidly, and the course progressed to uneventful recovery and discharge from the hospital on the 21st hospital day.

Two months after admission the white-cell count was 10,400, with 6 per cent stab and 54 per cent segmented neutrophils, 39 per cent lymphocytes and 1 per cent monocytes. The hemoglobin was 13.7 gm. per 100 cc., and the red-cell count 4,920,000.

DISCUSSION

A point of interest was that the patient, on admission, was estimated to be six and a half months pregnant. Seven weeks after admission she was readmitted to the hospital for delivery and gave birth to a normal living female child weighing 3 kg. (6 pounds, 9 ounces). The child, a month later, was thriving. The mother had remained clinically well since the time of initial discharge.

SUMMARY

A case of agranulocytosis due to drug reaction in pregnancy, treated with antibiotics, ACTH and cortisone, with recovery, is reported. A normal, living child was delivered.

REFERENCES

1. Hart, F. D., Wraith, D. G., and Mansell, E. J. B. Agranulocytosis successfully treated with ACTH. *Brit. M. J.* 1:1273-1275, 1952.
2. Virkkunen, M. Corticotropin and cortisone in treatment of agranulocytosis and thrombocytopenic purpura: report of four cases. *Arch. Int. Med.* 90:580-586, 1952.
3. Manning, I. H., Jr. ACTH and cortisone in treating blood disorders. *GP* 9:34, 1953.
4. Flinn, J. H., and Cullnane, C. W. Treatment of agranulocytosis with ACTH. *Jackson Clin. Bull.* 16:11, 1954.

*From the Henry W. Putnam Memorial Hospital.

†Member, active staff, Department of Internal Medicine, Henry W. Putnam Memorial Hospital.

‡Pathologist, Henry W. Putnam Memorial Hospital.

§Chief of staff, Henry W. Putnam Memorial Hospital.

HYDROCORTISONE OINTMENT IN THE TREATMENT OF INFANTILE ECZEMA

LEWIS WEBB HILL, M.D.*

BOSTON

HYDROCORTISONE ointment has been found to be valuable in the treatment of some cases of eczema.[1-4] As far as I know, there are only two reports to date devoted exclusively to its use in infants and children.

McCorriston[5] treated 104 children, in all of whom the hydrocortisone ointment produced greater im-

*Formerly, chief, Allergy Section, Children's Medical Center.

provement than the control base alone. In very severe cases the 2.5 per cent ointment was more, and in most patients the 1 per cent was equally effective.

Witten et al.[6] treated 30 infants and young children, with a favorable response in 18. In spite of this not very high rate of good results (60 per cent) they regard this as the simplest, cleanest and most rapidly effective of all the topical measures employed in the treatment of infantile eczema.

I have treated 110 infants and children suffering from contact or atopic dermatitis with hydrocortisone ointment.* Results were excellent in 81 (73.6 per cent) and poor in 29. We have used the ointment for the most part on relatively small areas. For the cheeks of a baby, provided there is not much crusting, a 5-gm. tube suffices for two daily applications for about six days. The back of a three-year-old child was treated with daily applications to an area measuring approximately 30 by 19 cm. It was found that a 5-gm. tube provided three applications. The ointment has excellent covering power, and a little goes a long way. It should be applied twice a day and well rubbed in. For most cases the 1 per cent ointment seems to work as well as the 2.5 per cent, and because it costs only half as much it is best to start with this strength.

It is considered best not to use hydrocortisone ointment, with or without neomycin, when infection is present even though there may be no actual pustulation. In 2 infants with crusted oozy faces the use of hydrocortisone ointment in a few days caused swelling of the face and marked lymph-node enlargement. In 1 of these patients the ointment without neomycin had been used, and when this was changed to the ointment with neomycin the swelling and glandular enlargement were soon relieved. In the other, however, the same situation developed while hydrocortisone ointment was combined with neomycin. In another infant innumerable small, semipurulent vesicles appeared over the face while the ointment with neomycin was being used. A boy with atopic dermatitis manifested many small pustules over the forearms during therapy with hydrocortisone ointment. Pustules on the ankles appeared in another patient with eczema of the ankles while she was being treated with 2.5 per cent hydrocortisone ointment with neomycin.

Although there was no gross evidence of infection in any of these cases when treatment was begun, staphylococci or streptococci were probably present in large numbers in the lesions, as in many cases, so that local resistance was altered by the hydrocortisone.

*Kindly supplied by Merck and Company, Rahway, New Jersey, and the Upjohn Company, Kalamazoo, Michigan.

Hydrocortisone ointment is most efficient in superficial scaly or erythematous areas. It does well for intertrigo, and for the small fissures often seen at the lobe of the ear and on the fingers. It works quickly; sometimes, little or no dermatitis is seen after two or three applications. Coincident with this the itching is relieved. However, recurrence is likely, and it is necessary to continue the use of the ointment over a considerable period to obtain really good results. The ointment is of little value for deep-seated papules, for faces with much crusting or for most sluggish thickened lesions with lichenification and little inflammation.

There are apparently few disadvantages to hydrocortisone ointment except that it is expensive; however, much ointment can be bought for what it costs to hospitalize a child for one day, and for small areas the expense is not great. If large areas are to be treated, expense is certainly a consideration. It is probably true that the action of hydrocortisone ointment is almost entirely local, although some is probably absorbed. In a 5-gm. tube of the 2.5 per cent ointment there is 125 mg. of hydrocortisone, and it seems quite possible that if large areas are treated there could be enough absorption to produce systemic and other deleterious effects. To date no systemic effects have been reported.

Conclusions

Hydrocortisone ointment is a valuable preparation for the treatment of some cases of eczema in infants and children.

In my opinion it is best not to use the ointment on areas where bacterial infection is present.

Hydrocortisone ointment by no means replaces all other methods of local treatment, for in some cases it is of no value whatever. There is still plenty of use for the local remedies that have been valuable for a long time in the treatment of eczema.

319 Longwood Avenue

References

1. Sulzberger, M. B., and Witten, V. H. Effect of topically applied compound F in selected dermatoses. *J. Invest. Dermat.* 19:101, 1952.
2. Sulzberger, M. B. Present status of hydrocortisone acetate ointment in dermatologic therapy. *Arch. Dermat. & Syph.* 68:451, 1953.
3. Kile, R. L. Use of hydrocortisone-neomycin ointment. *Ohio State M. J.* 49:1097, 1953.
4. Robinson, H. M., Jr., and Robinson, R. C. V. Treatment of dermatoses with local application of hydrocortisone acetate. *J.A.M.A.* 155:1213-1216, 1954.
5. McCorriston, L. R. Hydrocortisone (compound F) acetate ointment in eczema of infants and children. *Canad. M. A. J.* 70:59-62, 1954.
6. Witten, V. H., Amler, A. B., Sulzberger, M. B., and DeSanctis, A. G. Hydrocortisone ointment in treatment of infantile eczema. *Am. J. Dis. Child.* 87:298-304, 1954.

CASE RECORDS
OF THE
MASSACHUSETTS GENERAL HOSPITAL

Weekly Clinicopathological Exercises

FOUNDED BY RICHARD C. CABOT

BENJAMIN CASTLEMAN, M.D., *Editor*

VIRGINIA W. TOWNE, *Assistant Editor*

CASE 41241

PRESENTATION OF CASE

A fifty-four-year-old Armenian-born watchmaker entered the hospital after he was found to have a pulmonary lesion 2 cm. in diameter on a routine x-ray film of the chest a month before admission.



FIGURE 1. *Detail View of the Lesion in the Right-Upper-Lung Field, Showing It to Be Composed of Multiple Small Densities That Assume a Spherical Configuration.*

The patient had had x-ray films of the chest every year for five years but had not been told of any abnormality in previous films. There was no history of chronic cough, sputum, dyspnea, chest pain or weight loss. The past history was noncontributory except for chronic nasal discharge during the winter and some mild indigestion, for which he had been placed on a fat-free diet. He was said to have had a trachoma in the right eye as a child when he lived in Armenia. At the same time he had a severe illness characterized by swelling and draining abscesses in the submental regions. During this illness he was "given up for hopeless." He stated that he smoked a package of cigarettes a day.

Physical examination was entirely negative.

The temperature was 98°F., and the pulse 80. The blood pressure was 160 systolic, 80 diastolic.

The urine had a specific gravity of 1.022 and was normal. Examination of the blood revealed a hemoglobin of 15.8 gm. per 100 cc. and a white-cell count of 8300, with 69 per cent neutrophils, 28 per cent lymphocytes, 1 per cent monocytes and 2 per cent eosinophils. The sedimentation rate was 8 mm. per hour. Sputum smears were negative for acid-fast bacilli, sulfur granules and malignant cells. Culture of sputum on a blood-agar plate and in thioglycolate broth revealed only nonhemolytic streptococcus. A tuberculin skin test with 0.1 cc. of 1:10,000 tuberculin was positive. Bronchoscopy showed no abnormalities, and smears of bronchial washings were negative for tubercle bacilli, echinococcus hooklets and sulfur granules. An x-ray film of the chest revealed multiple small irregular areas of density in the right upper lobe forming a spherical mass 6 cm. in diameter (Fig. 1). Laminagrams of the lungs obtained at distances of 5, 6, 7, 8 and 9 cm. from the posterior chest wall suggested that the greatest number of dense areas were situated peripherally and that the center of the mass might contain air (Fig. 2). A large blood vessel appeared to traverse the mass, and there was a suggestion of a bronchus entering it. No enlarged lymph nodes were recognized.

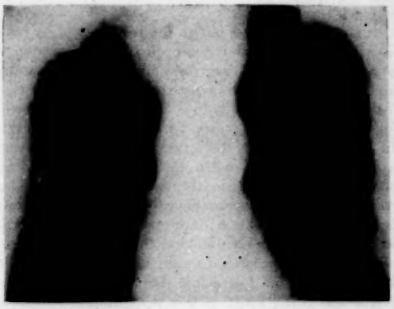

FIGURE 2. *Anteroposterior Laminogram of the Chest, Showing the Greater Number of the Densities to Lie Peripherally.*

The patient was discharged and was readmitted two weeks later for an operation.

Differential Diagnosis

Dr. Richard V. Wilson*: I have more information about this patient than is given in the protocol because I know that he has been cured. Yesterday afternoon, five years after his operation, I fluoroscoped him and came to the conclusion that he had had either a resection of the right upper lobe or a segmental resection of the lobe. All I could see were normal postoperative changes. I asked him about symptoms, and he said that he had none. I could have quickly avoided discussing this case if I had asked him why the surgeon operated; I did not ask him because earlier in the day, when I put the same question to another patient, on whom I had no clinical information, she became quite indignant that I did not know all about her and she gave me the impression that she thought that I had no right to examine her. It was later in the afternoon that I was told that I had fluoroscoped the man that I was to discuss today.

I am dealing with an asymptomatic lesion of the chest in a man of fifty-four years. I disagree somewhat with the protocol in calling this a mass. I should call it a group of tiny nodules arranged in a circular fashion about a center of comparatively normal lung. It is situated in the posterior segment of the right upper lobe. It does not change over a two-week interval. On the magnification film the calcifications are best demonstrated (Fig. 1). On one tomogram there is a vessel that seems to go across this lesion and a bronchus that enters it (Fig. 2). There are no enlarged lymph nodes in the hilar area.

I think I can exclude neoplasm because I have never seen a primary bronchogenic or metastatic lesion that gave this picture. Could it have been early pulmonary adenomatosis? There are individual nodules on the x-ray film. In the cases of pulmonary adenomatosis that I have seen the nodules have not been this discrete. Also, the patient had no dyspnea, cough or thick slimy sputum. Could it have been lymphoma? With pulmonary infiltrates in lymphoma there are usually enlarged lymph nodes somewhere. On physical examination he had no enlarged lymph nodes, and I see none in the hilar or peritracheal areas.

When I see weird x-ray pictures (and I consider this a weird one) among the conditions I consider are the "collagen" diseases, but clinically they can be excluded because the patient was asymptomatic. Mineral-oil pneumonitis certainly occurs in the posterior segment of the right upper lobe but usually presents a ground-glass homogeneous density, and this did not. In the early stage of conglomerate silicosis the lesions look like this. This man had no history of exposure, but I do not know what work he had done all his life; all I know is that at the time of admission he was a watchmaker. When I see lesions such as this in my daily work, and I really seriously consider an occupational disease, I ask the patient about his work.

*Assistant radiologist, Massachusetts General Hospital.

Dr. Helen S. Pittman: There was no more occupational history. He had been a watchmaker, and he had run a little shop in which food, cigarettes and things of that sort were sold. That is the only occupational history I have been able to obtain.

Dr. Wilson: In all the cases of conglomerate silicosis that I have seen, there have been a few nodules elsewhere in the lung. Moreover, although silicosis is an entity that gives an x-ray picture much more pronounced than the clinical picture that the patient presents, the x-ray densities are more homogeneous and less nodular than this. I exclude silicosis. Another lesion that will give this x-ray picture is Loeffler's syndrome, but there is no change in the picture in the two-week period. A different picture was described a month before admission, but I shall disregard that because the lesion remained essentially the same for two weeks and has the appearance of a lesion that has been the same for a while. Also, the patient had no eosinophilia. I do not think this was sarcoidosis because the tuberculin test was positive. In sarcoidosis enlarged lymph nodes, diffuse miliary nodules or interstitial fibrosis is usually seen, and none of them were present here.

Then I come to the fungi. The history suggests that the patient may have had actinomycosis when he was a child. I believe that it is exceedingly unlikely that this was secondary spread from the primary disease after approximately thirty years had intervened during which he had no symptoms. Also, if there had been direct spread from the primary infection, there should have been involvement of the paraspinal tissues, which is not shown in the films. If the spread had been hematogenous there would have been more than one focus. Could it have been primary actinomycosis or primary fungous infection of some other sort? Usually, with actinomycosis, at least later, there is involvement of the pleura or of the thoracic cage, neither of which was evident. Normally, with actinomycosis, the lower lobes are affected; this was an upper-lobe lesion. Usually, the shadow is more homogeneous. Radiologists frequently describe ring shadows with fungous infection, particularly with coccidioidomycosis, but the ring shadows, the target shadows, of the lung that have been described have been more sharply demarcated than this one. This is not my impression of what is meant by a ring shadow. If I am wrong about this point I have totally missed this case, because I have interpreted this as not being the ring shadow of coccidioidomycosis. We see very little fungous infection in New England. This man apparently had not lived in the regions in which these infections are common — such as the Southwest, with coccidioidomycosis, and the Mississippi and Ohio Valleys, with histoplasmosis. However, whenever there is a weird x-ray appear-

ance, I think one has to consider seriously fungous infection. I cannot exclude a primary fungous infection.

Was this bronchiectasis? I do not see any dilated bronchi. There could have been a nonspecific chronic pneumonitis without bronchiectasis, but that would not explain the calcifications. Usually, there is some degree of atelectasis, the density is more homogeneous, and there is more fibrosis.

Tuberculosis can do this. When I first saw the films, that was my impression. The calcifications and the location in the lung go along with tuberculosis. With a lesion of this size, however, one would like to see evidence of tuberculosis elsewhere in the lung, and I do not see it. The cytologic examination was negative, but perhaps the lesion did not communicate with a bronchus. If this was tuberculosis, I do not believe that it was inactive.

It is my conclusion that I am dealing with an inflammatory process and that pathologically a small nodular granulomatous lesion was found. The type of infection bothers me. If I could say that it was a chronic granulomatous process, I should be fairly sure that I should be correct. I think I should be more specific; therefore, I shall list my diagnoses in the order of choice. I should put tuberculosis first chiefly because of the location of the lesion in the lung, the calcifications in the lesion and the fact that I have seen it give this type of picture more frequently than anything else. For the second choice, despite the fact that this patient had lived in recent years in New England, I should say this was a primary fungous infection and had no relation to the draining sinuses in childhood. For the third choice, I should take a nonspecific chronic pneumonitis.

DR. AUSTIN L. VICKERY: Dr. Pittman, should you like to make any comments?

DR. PITTMAN: This man had routine survey films as a food handler. In December, 1948, a small survey film was interpreted as normal. In the following year another survey film was regarded as abnormal, and the patient was sent to my office. We did not know what he had. The films were reviewed at x-ray seminar. No one had seen lesions of quite this appearance. The radiologists believed it was probably not neoplastic or tuberculous, although the question of adenomatosis was raised. The patient was operated on because we knew this lesion was of not over a year's visible duration and we did not know what it was. When the American College of Physicians met here about five years ago this case was fresh, and it was discussed over a closed television circuit. Dr. Sosman was on that panel. He is here today; I wonder if he would like to comment.

DR. MERRILL C. SOSMAN: I do not remember anything about this case at all although I was on the panel. I think that Dr. Wilson has discussed it adequately. One bad habit to get into is to try to make the diagnosis because one has seen a similar picture before. It is much better to analyze the process going on in the patient as the pathologist does — I hope he does — and decide what the reaction we see means. I think we can conclude that this was an inflammatory process — a low grade inflammatory process without a definite cavity — rather than a neoplastic one and that the two most probable etiologic agents are tubercle bacillus and fungus. I think this is as much as anybody can say with any logic.

DR. VICKERY: Are there any other comments?

DR. BRIANT L. DECKER: Did the patient keep chickens, or did he have a little garden?

DR. PITTMAN: No.

CLINICAL DIAGNOSIS

?Benign tumor of lung.

DR. RICHARD V. WILSON'S DIAGNOSIS

Tuberculosis.
?Fungous infection.

ANATOMICAL DIAGNOSIS

Pulmonary tuberculosis.

PATHOLOGICAL DISCUSSION

DR. VICKERY: The pathological findings in this case will be discussed by Dr. Manuel Straub, who is visiting the laboratory this week. Dr. Straub is the chief pathologist to the Municipal Hospitals in Rotterdam, the Netherlands, and has been particularly interested in this type of disease and pulmonary problems in general.

DR. MANUEL STRAUB: I am very happy to speak at a clinicopathological conference at the Massachusetts General Hospital. I have read many of these clinicopathological cases in the *New England Journal of Medicine*, but I never thought that I should ever have the opportunity to speak here.

Resection of the upper lobe of the right lung was done. In general the lobe was hypercrepitant and emphysematous. In the posterior segment there was an ill defined area of increased density radiating from the hilus and measuring roughly 6 by 5 cm. (Fig. 3). The specimen, on the surface and on being sectioned, was granulomatous, the granulomas measuring from 1 to 3 mm. and fanning out from the hilus to the periphery. Between the nodules the pulmonary tissue was more emphysematous than elsewhere. The bronchi were dilated but were not otherwise affected. About the hilus were some anthracotic lymph nodes, the largest of which contained a granulomatous lesion similar to that in the lung. Microscopically, the granulomas were of the productive type and mainly interstitially situated, but some small lesions of caseous bronchitic and peribronchitic

nature were found. The interstitial granulomas in the lung resembled those in sarcoidosis. The caseous peribronchitic lesions, however, were suggestive of tuberculosis. In former years pathologists would not have hesitated to say that this was tuberculosis, but nowadays we know that fungous diseases have to be taken into account. However, tubercle bacilli were obtained from guinea pigs inoculated with this material so that there is no doubt that these lesions were tuberculous although of an extraordinary configuration in the x-ray picture.

This is not a tuberculoma. What is a tuberculoma? We in the Netherlands are rather strict about the diagnosis of tuberculoma and have come to the following definition: a tuberculoma is a dry, caseous, postprimary tuberculous lesion arising by collateral inflammation in the pulmonary tissue around a focus of liquefying caseous bronchitis. The main point is that the central part of a tuberculoma is liquefying caseous bronchitis. To illustrate the nature and pathogenesis of tuberculoma I shall show some pictures mainly taken from the thesis of Willemse,[3] working in the laboratory of Professor P. Nieuwenhuyse, of Utrecht. This photograph (Fig. 4) is of a



FIGURE 3.

tuberculoma, showing the dry caseous appearance, the distinctly laminated character and the central caseous bronchus. Figure 5 shows multiple tuberculomas in an upper lobe in their relation to the bronchi. Figure 6 is a diagram of another case constructed after serial section of the whole lobe. There are four different tuberculomas hanging on the bronchial tree. The areas of bronchitis are the only places where the tubercle bacilli are found. In those areas cavitation can occur, and a few bacilli can be released into the sputum. I spoke about collateral inflammation as the cause of the laminated structure. Organizing collateral pneumonia around the central caseous bronchitis causes the rings of collagen that are responsible for the laminated structure. The pneumonia is the consequence of a stream of diffusion of toxic material from the center to the periphery. This diffusion is also shown by the fat stain. The fat in the tuberculoma is deposited in the same laminated fashion as the collagen.

FIGURE 4.

A comparison of these photographs with the lesion under discussion shows that they are completely different except that both are in my opinion postprimary lesions. The scar of the fistulating process in the neck that the patient had when he was eight years old suggests that this may have been of primary tuberculous origin. If so, the pulmonary lesion that was found on admission must be considered to be a reinfection. The lesion, however, is not the result of collateral inflammation but of lymphogenic spread to the hilar lymph nodes. Similar lesions are often found accidentally in the lungs of older patients who have never had any symptoms of tuberculosis and who die from causes other than tu-

berculosis. In Holland we find such postprimary apical and subapical lesions in patients with healed remnants of bovine mesenteric tuberculous infection so that we know that they are the result of exogenous reinfection. Exogenous reinfection is not just a theoretical reconstruction but, as Terplan,[2] of

FIGURE 5. *Multiple Tuberculomas (Reproduced from Willemse[1] with the Permission of Professor P. Nieuwenhuyse).*

Buffalo, has clearly shown, a reality. We might call the lesion under discussion a progressive reinfection complex. A difficulty is that these subapical reinfections have a chronic course of many years. In this patient, a year before the lesion was noted, nothing was found in the x-ray film. I therefore suggest that the lesion was present for a long time but that it became visible on the x-ray film only when the lung tissue around the interstitial process became emphysematous and especially when the area in the center of the lesion became very emphysematous.

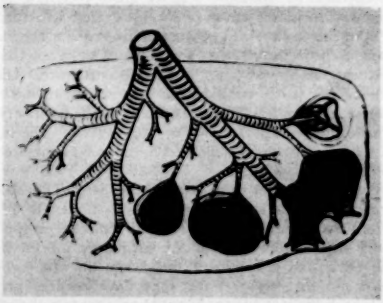

FIGURE 6. *Tuberculomas of the Bronchial Tree (Reproduced from Willemse[1] with the Permission of Professor P. Nieuwenhuyse).*

DR. VICKERY: Dr. Pittman, will you tell us how the patient was after discharge?

DR. PITTMAN: After discharge from the hospital I saw him at fairly frequent intervals for sixteen months. He did very well and returned to light work. He continued to smoke a package of cigarettes a day. He had no cough, essentially no sputum and a little pain in the wall of the chest. A first-strength P.P.D. tuberculin test a year after operation showed 1 cm. of erythema and 3 mm. of induration.

I did not see the patient again until recently, five years postoperatively. He had no cough, fever, sweating or chest pain. He continued to raise a little clear sputum. He had had one cold in the past year. His weight has remained unchanged. As Dr. Wilson mentioned earlier his current x-ray films show only postoperative changes.

REFERENCES

1. Willemse, F. M. H. *Morphologisch onderzoek van het Tuberculoma pulmonis.* Utrecht thesis, 1953.
2. Terplan, K. Anatomical studies on human tuberculosis. *Am. Rev. Tuberc.* Supp. 42:1-176, 1940.

CASE 41242

PRESENTATION OF CASE

A fifty-five-year-old man was admitted to the hospital because of severe epigastric pain.

For the preceding five or six weeks he had not felt well, but had had no specific complaints. When he was seen by his private physician five weeks before admission, examination of the blood revealed a hemoglobin of 13.4 gm. per 100 cc., a red-cell count of 3,900,000 and a white-cell count of 2500, with 61 per cent neutrophils, 26 per cent lymphocytes, 8 per cent monocytes, 4 per cent eosinophils and 1 per cent basophils. A smear showed slight to moderate macrocytosis, slight anisocytosis and slight poikilocytosis of red cells, with occasional target cells and ovalocytes. The platelets appeared normal. Two weeks before admission an upper gastrointestinal series done at another hospital revealed a duodenal deformity, and a Graham test disclosed a poorly filling gall bladder but no stones. A barium-enema examination showed no abnormalities except for the presence of the cecum and appendix in the right upper quadrant; the spleen was moderately enlarged. The white-cell counts at this time were 2700 and 3900, with 56 per cent neutrophils, 42 per cent lymphocytes and 2 per cent eosinophils. Ten days before admission the patient had a pleuritic type of discomfort over the right inferior anterolateral chest wall, accentuated by respiration. This discomfort lasted for five or six days. He also noted a feeling of fullness after eating or drinking and slight tenderness at first in the right flank and right lower quadrant and then in the left flank and left lower quadrant. One week before admission he took a laxative for the vague abdominal discomfort, without benefit. Two days later he experienced a severe crampy pain in the epigastrium that soon became generalized and lasted twelve hours. Eighteen hours before admission he noted aching discomfort in the right shoulder. Three

hours before entry, shortly after eating breakfast, he suddenly experienced crampy epigastric pain, which became generalized and was associated with slight nausea and an episode of nonbloody vomiting. He promptly became weak and sweaty and was referred to this hospital.

The patient was a maintenance worker in a manufacturing plant and frequently had handled metallic mercury, had used butyl acetate as a cleaning solution and had had some exposure to carbon tetrachloride. He did not drink alcoholic beverages; he smoked cigarettes regularly, but in the past three weeks had not smoked. He gave a history of postprandial distress and hunger pains relieved by food for the past ten to fifteen years, and though advised to follow an ulcer regimen he had never done so. He denied tarry stools, nausea and vomiting. For the past month he had noted a minimal degree of ankle swelling in the evening, which usually subsided by morning.

Physical examination revealed a very pale man with a warm, dry skin and a face covered with sweat. Examination of the lungs and heart was negative. The abdomen was distended, tympanitic and soft to palpation; there was slight tenderness in the flanks. A moderately tender mass was palpated in the left upper quadrant 2 or 3 fingerbreadths below the costal margin. Peristalsis was present but reduced. Rectal examination was negative. There was slight ankle edema.

The temperature was 97.4°F., the pulse 90, and the respirations 18. The blood pressure was 90 systolic, 50 diastolic.

Examination of the urine showed a specific gravity of 1.035, with a light-green sugar reduction, a + + + test for albumin and negative tests for acetone and bile; the sediment contained 7 white cells, rare epithelial cells and numerous bacteria and hyaline casts per high-power field and 3 pigmented casts per low-power field. Examination of the blood revealed a hemoglobin of 9.1 gm. per 100 cc., a hematocrit of 25 per cent and a white-cell count of 6400. A stool gave a negative guaiac test. Gastric aspiration provided 50 cc. of guaiac-negative fluid that contained no free acid. The serum amylase was 10 Russell units. An x-ray film of the chest showed elevation of both leaves of the diaphragm, more marked on the right side. The lungs were clear but were hypoventilated because of the high diaphragm. There was no evidence of free air under the diaphragm. A lightly exposed film of the abdomen showed a diffuse haze, interpreted as either incomplete penetration or free fluid in the peritoneal cavity.

The patient's condition remained the same for the next three hours while he received whole-blood transfusions in preparation for surgery. Three hours after admission there was a striking change in the abdominal findings. The abdomen was now doughy and dull to flat on percussion, and a fluid wave was elicited. An operation was performed.

Differential Diagnosis

Dr. Edward Hamlin, Jr.*: May I start by seeing the x-ray films?

Dr. C. C. Wang: I do not have the films taken at the other hospital. The x-ray examinations of the chest that were done in this hospital show a markedly elevated diaphragm, particularly on the right side. The lung fields are clear. There is no evidence of free air beneath the diaphragm. The films of the abdomen reveal diffuse haziness throughout, suggesting the presence of free fluid in the peritoneal cavity. The right psoas-muscle shadow is not so well seen as the left. Gas is scattered through the large and small bowel; no localized dilatation, gallstones or unusual soft-tissue masses are recognized.

Dr. Hamlin: Is there anything that you can say about the spleen? Left-upper-quadrant tenderness was mentioned.

Dr. Wang: The spleen does not appear greatly enlarged; I can see its medial border lying in fairly normal position.

Dr. Hamlin: That is helpful.

I think it is better to start at the end and work toward the beginning. Just before operation the patient had a distended abdomen, which was dull and had a fluid wave; on that basis, together with the x-ray evidence, I can certainly say that he had free fluid in the peritoneal cavity. Certainly, no description in the protocol suggests peritonitis in any severe form. I should expect some spasm, much more tenderness on palpation or cough, pain or something of that sort to give me a lead if there had been any degree of peritonitis. Therefore, I can argue that the fluid in the peritoneal cavity was not of the type that produces much peritoneal irritation. There was also good evidence that he had undergone a fairly rapid blood loss; the hemoglobin had fallen in five weeks from 13 gm. to 9 gm. per 100 cc., and the hematocrit was only 25 per cent. It seems reasonable, therefore, to argue that the abdomen contained blood. Blood in the abdomen, although mildly irritating to the peritoneum, does tend to produce the type of picture that was described — doughy abdomen containing fluid but without giving evidence of peritonitis.

So this man had blood in the abdomen, was quite sick and had this background of peculiar events. I have to explain where the blood came from. I am glad to see spontaneous rupture of the spleen, which certainly was implied in the protocol, minimized by Dr. Wang in his interpretation of the x-ray films. That is a very rare entity. There are reports of its having occurred with malaria and with mononucleosis; undoubtedly, it has occurred with many conditions involving the spleen. There was no history of trauma so if the spleen ruptured, it was indeed a spontaneous rupture. There is in the protocol the remark that a slightly tender mass was found in the left upper quadrant. That may have been spleen that was not shown

*Associate visiting surgeon, Massachusetts General Hospital.

in the plain film of the abdomen. I am relieved to find evidence that it was not spleen, for I should make a diagnosis of spontaneous rupture of the spleen only with great hesitancy. Moreover, none of the other factors would be easily explicable by that condition, particularly since all the evidence points to the right rather than the left side of the abdomen.

What other sources of bleeding are there? The liver as a source of bleeding from the point of view of the record is a better possibility because it would explain the symptoms, which were predominantly right sided. The pain was more pronounced on the right side in each instance, and the x-ray films showed the right leaf of the diaphragm to be considerably higher than the left, so that I am much more comfortable talking about the liver than the spleen as the source of bleeding in this patient.

I am at a loss to name other sources of hemorrhage; I suppose that any organ conceivably might rupture. I cannot recall ever having heard of a spontaneous rupture except of an aneurysm. I suppose the patient could have had an aneurysm of one of the vessels, with perforation into the abdominal cavity. That would be such a wild shot in the dark that I should prefer to dismiss it. He was exposed to various commercial poisons such as carbon tetrachloride and butyl acetate. I know nothing about butyl acetate, and I have not had a chance to look it up either, but I assume that it is toxic to the liver somewhat as carbon tetrachloride is. Of what significance might that be? I am carefully not going to ask the extent of the exposure because it might destroy my thesis. If the exposure was over a long period it is possible that he became intoxicated and that liver disease, notably cirrhosis, developed. Then, after a long period, a hepatoma may well have developed.

I do not know much about hepatomas; I never happened to encounter one in an operation. It is known that they may bleed. I think that one could make a plausible account of a liver that had been sick for a long time, in which a hepatoma developed. Perhaps minor hemorrhage in the hepatoma had taken place, producing the symptoms of which the patient had complained in the few days before entry, and at the time of entry or shortly before, rupture into the peritoneal cavity had occurred. That would explain to some extent the leukopenia; it would take into account the fact that he was exposed to these poisons; it would account for practically all the details that were offered except the evidence of a duodenal ulcer and perhaps of chronic cholecystitis, which I prefer to interpret as "red herrings." Therefore, I believe that this man had a hemorrhage from a ruptured hepatoma of the liver.

DR. CHESTER M. JONES: I think there is no reason to doubt that he had intrahepatic disease. Where there is chronic liver disease and portal hypertension the bleeding is either into the stomach or the esophagus or rarely into the region of the colon from intraluminal varicosities. So far as the evidence is presented there is no reasonable suggestion that the drop in hemoglobin was due to bleeding into the gut. I wonder if he had bled into the peritoneal cavity. Was a needle put into the peritoneal cavity?

DR. RICHARD B. COHEN: I do not believe so.

DR. WALTER BAUER: I must say that Dr. Hamlin has stepped right along. I, like Dr. Jones, believe that the patient probably did have hepatic disease. I, like my seat mate, Dr. Kranes, was thinking he probably had a ruptured spleen. I do not remember having seen or heard of a ruptured spleen in a man with cirrhosis associated with portal hypertension, but I should think it might happen.

DR. JONES: I do not believe he bled from the liver.

DR. BAUER: It is difficult to say that he did not have blood in the abdomen.

DR. JONES: I do not see how one can be sure without putting a needle in.

DR. BAUER: From the description of the physical findings I should say that he had free blood in the peritoneal cavity.

DR. JOHN G. FREYMANN: What was the racial background of the patient?

DR. COHEN: He was an Italian.

DR. FREYMANN: Palpable spleens are quite common in patients of Italian extraction, the enlargement probably being due to thalassemia minor.

DR. ALFRED KRANES: Was a blood smear done? I was thinking of infectious mononucleosis.

DR. COHEN: Yes; a blood smear was done; there was no evidence of infectious mononucleosis.

DR. DANIEL S. ELLIS: I was interested in Dr. Hamlin's comment that hemorrhage from the liver was more common than from the spleen. I had always thought the reverse to be true.

DR. HAMLIN: I do not want to flog a horse that is probably very dead. I did not make the diagnosis on that basis but on the basis that the patient had great pain and elevation of the right leaf of the diaphragm. I wanted to put the disease on the right side of the abdomen.

A PHYSICIAN: Had this man been in Italy recently, or did he come over as a young man?

DR. COHEN: I do not believe he had been there recently; I do not know whether he was born there or came over as a young man.

A PHYSICIAN: I was thinking of tuberculosis of the intestines.

DR. COHEN: Dr. Ellis, would you comment on the preoperative course?

DR. ELLIS: When the patient came into the hospital, he was acutely ill. I did not see him until three hours after admission, when I was asked to decide whether I thought he ought to be operated on. He was lying quietly in bed in no acute distress. It was obvious that he was pale, and in the ten minutes that I was in the room, I had the distinct impression that his face was growing more the color of the sheet and

that the abdomen was growing larger. The pulse was slow; he did not show any air hunger, and the abdomen was distended, obviously with fluid. There was no palpable mass because of the distention of the abdomen. I believed that he was bleeding into the peritoneal cavity and that the sooner he was operated on the better chance he might have of survival. We did not stick a needle into the abdomen because it seemed obvious that he was bleeding. Those of us who saw him were more concerned with the previous history of the leukopenia and the palpable spleen. The physician who saw him at the time of admission thought that the mass in the left upper quadrant was spleen. The preoperative diagnosis that I wrote in the record was intraperitoneal bleeding, probably from a ruptured viscus, with the spleen as my first choice and a ruptured bleeding ulcer as my second.

DR. JONES: The spleen was clearly felt early in the morning; is that correct?

DR. ELLIS: I was told that a mass was felt and was interpreted as spleen.

DR. JONES: If the patient had had a massive hemorrhage and cirrhosis, the spleen would have been increased in size anyway; if he had had a ruptured spleen, massive bleeding would probably have reduced the size of the spleen and rendered palpation difficult or impossible.

DR. ELLIS: One could not feel any masses at the time I saw him because of the distention of the abdomen with fluid.

DR. T. C. HALL: Apropos of the point about the liver and spleen, there was a recent case of spontaneous rupture of the spleen in a young woman with Hodgkin's disease; it was a Massachusetts General Hospital clinicopathological case,[1] and the proper diagnosis was made. Subsequently, there has been a report of a survey of the literature on rupture of the spleen with lymphoma. Twenty-five cases[2] were collected from the world literature, which does not include our patient, the 26th. The spleen in the patient under discussion may have been involved by leukemia, the fall in the hemoglobin from 13 to 9 gm. going with it; if there was no obvious source of bleeding, it may have been due to a hemolytic anemia.

CLINICAL DIAGNOSIS

Rupture of pathologic spleen.

DR. EDWARD HAMLIN, JR.'S DIAGNOSIS

Hemorrhage from ruptured hepatoma of liver.

ANATOMICAL DIAGNOSES

Ruptured hepatoma, with intra-abdominal hemorrhage.
Postnecrotic cirrhosis of liver.
Acute pancreatitis, terminal.
(Uremia.)

PATHOLOGICAL DISCUSSION

DR. COHEN: Since Dr. John B. McKittrick, who operated on the patient, is not here, will you comment on the operation, Dr. Ellis?

DR. ELLIS: When the peritoneum was opened, the operating table was covered with a gush of blood, coming out under some pressure. A quick palpation was made in the left upper quadrant to ascertain the status of the spleen. It was found to be of about normal size, and it apparently was not the source of the bleeding. It was finally ascertained that the blood was coming from the right side of the abdomen, and palpation over the right dome of the liver revealed a large mass there. After much suctioning, considerable free bleeding from this area was noted. The incision, which was a transverse incision on the left side, was quickly extended to make a right thoracoabdominal incision; this exposed the diaphragm, and a large mass covered with blood and blood clot was found. Attempts to suture the mass and stop the bleeding were unsuccessful so a pack of Gelfoam was put in, which also did not stop it. A search began for the hepatic artery. The main hepatic artery could not be identified, but a large vessel in the region of the cystic artery was found and was ligated. This did not stem the tide much so another vessel, probably the hepatic artery, was ligated. After five hours the bleeding was stopped. An anticoagulant pack over the dome of the liver was left in; the wound was sewed up. I think the patient had 11 transfusions on the table.

DR. COHEN: A biopsy on the liver away from the tumor showed a portal cirrhosis of the postnecrotic type in a very advanced stage. Of course, we did not receive any of the tumor; the surgeons did not biopsy it because of its apparent vascularity. Dr. Ellis will describe the subsequent course.

DR. ELLIS: It was not definitely ascertained at operation that there was neoplasm. The surgeons could not tell whether the bleeding was from a rupture of the liver, a vascular type of tumor or a hepatoma. The patient survived the procedure and for twenty-four hours showed no jaundice, excreted ample quantities of urine and was quite alert. After forty-eight hours the quantity of urine began to decrease. On about the third day he became jaundiced, and had considerable muscle twitching and an increasing nonprotein nitrogen level, but he did not have the flapping tremor associated with increasing blood ammonia level or hepatic coma. On the fifth or sixth day he became confused and had increased generalized muscle twitchings and marked oliguria. He died in coma with an elevated nonprotein nitrogen and diminished output of urine. Up until forty-eight hours before death I thought we were dealing primarily with renal failure. The jaundice, I suspect, may have resulted from one of several sources — the underlying liver disease, the operative procedure, with ligature of the hepatic artery, or hemolysis from the

tremendous amount of blood in the peritoneal cavity. We speculated about how much the ligation of what was thought to be the hepatic artery had accelerated the damage to the liver. At the end we believed that death was due to uremia and complete liver failure. The type of kidney disease was not clear to us. The liver failure was considered to be due to portal cirrhosis and probably infarction.

DR. COHEN: At autopsy the liver weighed 2000 gm. and was definitely cirrhotic. In the right lobe was a large well circumscribed tumor mass, which protruded under and elevated the diaphragm (Fig. 1). On the surface of this mass was a large blood clot that covered a disruption in the liver capsule into which tumor protruded. The tumor showed extensive necrosis (Fig. 2). Disseminated throughout the

FIGURE 1.

remainder of the liver were patchy irregular areas of yellow necrosis. Microscopical examination of liver sections revealed the tumor to be a very vascular hepatoma, the cell cords being separated by sinusoids distended with blood. The necrosis in the remaining liver tissue was characteristic of infarction. The difficulty in locating the hepatic artery at the time of operation was the result of a congenital variation. The right hepatic artery took origin from the superior mesenteric artery rather than from the trunk arising in the celiac plexus. A large vessel arising from the celiac plexus supplied the left lobe separately. The spleen was enlarged, weighing 600 gm., probably accounting for the leukopenia. Despite the severe uremia the kidneys showed little alteration other than some hydropic change in the proximal convoluted tubules. This is an example of the dissociation between the pathological and physiologic and chemical findings that is sometimes observed in these cases. It is probable that some of the newer technics of histochemistry and nephron dissection will reveal morphologic alterations not brought out by routine technics.

A surprise finding at autopsy was an acute, severe pancreatitis. The changes were very early and had probably been present for no more than the last four days of life. The blood supply to the pancreas was intact. I can suggest no etiology for it except that it may have resulted from the manipulation of the biliary tract during operation, a complication that occasionally occurs.

I think that Dr. Hamlin made a very astute diagnosis in this case. We have seen another case of bleeding hepatoma recently, but it is not a common complication.

DR. ELLIS: Was there any other disseminated tumor in the liver?

DR. COHEN: The yellow nodules were necrotic liver tissue. There was no tumor other than the circumscribed nodule in the right upper quadrant.

DR. ELLIS: The main hepatic artery came off from the celiac axis, and that was not ligated. It seemed to supply the left lobe of the liver. Was there infarction of the left lobe of the liver as well as the right?

DR. COHEN: Both lobes of the liver showed focal infarction. We could not explain that unless there was some additional anomalous intrahepatic flow that interfered with the ligation of the right hepatic artery.

DR. ELLIS: I am surprised that the blood flow to the left lobe of the liver was impaired at all. At autopsy I believe the patient had a large vessel, which was not tied, going freely into the left lobe of the liver.

FIGURE 2.

DR. COHEN: We were also surprised by that. We cannot explain it adequately. There was necrosis in both lobes of the liver, more marked in the right lobe but definitely present in the left.

REFERENCES

1. Case Records of the Massachusetts General Hospital (Case 40352). *New Eng. J. Med.* 251:400-403, 1954.
2. Custer, R. P., Gunter, M. J., Warren, S., and Collier, F. C. On mechanism of unexpected (so-called spontaneous) rupture of spleen in malignant lymphoma. Presented at the meeting of the American Association of Pathologists and Bacteriologists, Houston, Texas, April 9, 1955.

The New England Journal of Medicine

Official Organ of
THE MASSACHUSETTS MEDICAL SOCIETY

OWNED BY THE SOCIETY AND
PUBLISHED WEEKLY UNDER THE JURISDICTION OF THE
COMMITTEE ON PUBLICATIONS

Richard M. Smith, M.D., *Chairman*
James P. O'Hare, M.D. Richard E. Alt, M.D.
Oliver Cope, M.D. James M. Faulkner, M.D.

Joseph Garland, M.D., EDITOR
ASSOCIATE EDITORS
Thomas H. Lanman, M.D. Donald Munro, M.D.
Theodore H. Ingalls, M.D.

Clara D. Davies, EXECUTIVE EDITOR
Robert O'Leary, ASSISTANT EDITOR
James F. Ballard, BOOK REVIEW EDITOR
Milton C. Paige, Jr., BUSINESS MANAGER

EDITORIAL BOARD
Henry R. Viets, M.D. Benjamin Castleman, M.D.
Robert M. Green, M.D. J. Englebert Dunphy, M.D.
Dwight O'Hara, M.D. Robert W. Buck, M.D.
Fletcher H. Colby, M.D. Herrman L. Blumgart, M.D.
Robert L. Goodale, M.D. Frank N. Allan, M.D.
Chester M. Jones, M.D. Harvey A. Kelly, M.D.
Harvey R. Morrison, M.D. Langdon Parsons, M.D.
Maxwell Finland, M.D. Mark Ainser, M.D.
Vernon P. Williams, M.D. Walter F. Lever, M.D.

SUBSCRIPTION TERMS: $8.00 per year in advance, postage paid, for the United States (first-year interns and medical students, $5.00 per year); Canada, $9.00 per year (Boston funds); foreign, $10.50 per year. Long-term rates: United States, 2 years $15.00, 3 years $22.00; Canada, 2 years $17.00, 3 years $25.00; foreign, 2 years $20.00, 3 years $29.50.

MICROFILM volumes available to regular subscribers through University Microfilms, 313 N. First Street, Ann Arbor, Michigan.

MATERIAL, other than original articles, should be received not later than noon on Thursday, three weeks before date of publication.

THE JOURNAL does not hold itself responsible for statements made by any contributor.

COMMUNICATIONS should be addressed to the *New England Journal of Medicine*, 8 Fenway, Boston 15, Massachusetts. Telephone KE 6-2094.

MANUSCRIPTS, including references or bibliography, should be typewritten double spaced and submitted as original copy. References should conform to the style of the *Quarterly Cumulative Index Medicus* (listing name and initials of author, title of article, journal, volume number, first and last pages and year), and should be cited numerically in the order in which they appear in the text; the number should be limited to the absolute minimum.

ILLUSTRATIONS are reproduced as half tones and zinc etchings. Photographs must be distinct, and drawings done in black ink on white paper and each properly labeled.

MATERIAL printed in the *New England Journal of Medicine* is covered by copyright. Articles are accepted for consideration with the understanding that they are contributed for publication solely in this journal.

"WINNOWING BREEZE OF FREEDOM"

McGEORGE Bundy, professor of government and dean of the Harvard Faculty of Arts and Sciences, appeared by invitation last March before the Subcommittee on Reorganization of the Committee on Government Operations of the United States Senate, to make a statement regarding the relations of the University to government security policy. This eloquent expression of principles as well as of policies appeared in the *Harvard Alumni Bulletin* on April 9, 1955.

Dean Bundy's statement is divided into three parts, the first two, representing the official attitude of the University, dealing with its general policy toward government security and its specific procedures in the handling of government contracts. The third part represents an expression of his personal opinion, widely shared among his colleagues, "of the effect of present security policy — or lack of policy — on the advancement of knowledge and the national welfare and safety."

Except in a time of such national emergencies as overt war, Harvard University holds to a policy of open research in basic subjects, and consequently shuns secret contracts and the restricting responsibility of working with classified material. Such a policy is in line with the conviction that the greatest contribution a center of learning can make is through unrestrained advancement of the truth by teaching and research — a contribution requiring "scholarly excellence and total freedom of inquiry."

To carry out its proper functions in the pursuit and dissemination of knowledge, a university must gather to itself men of first-rate intellect. They must not be rascals, as Professor Bundy expresses it, and he accepts this liberal criterion as a standard that excludes Americans who still submit to Communist discipline. Otherwise the standards of the University "include a deep regard for the right of a colleague to his own honest convictions and his own choice of action."

The cherished academic independence characterizing the ideal university was clearly stated by President Eliot in his inaugural address within a decade of the termination of another great war. "Above all," he said, "it must be free. The winnowing breeze of freedom must blow through all its chambers. . . An atmosphere of intellectual freedom is the native air of literature and science." This breeze can be stifled by contracts requiring secrecy and intellectual and physical barriers between departments. True academic freedom, however, works both ways; it also permits the participation of the individual in secret work with the blessing of the University, but at his own discretion and not in a manner that involves his department.

Dean Bundy's personal opinions relate to the present security program, the intimation being that many of its policies are developed by men some of

whom are unacquainted with the problems on which they are passing judgment. The program has thus tended to become "an instrument of insecurity and mistrust among men of good sense and high character." Equally pernicious is the policy of deep distrust of America that seems to prevail in certain government agencies, where there are those who believe that the American people must be protected from Soviet documents and inferentially from any knowledge of the forces and ideologies that are threatening their security from the outside.

Scientists remain ready to help their government when needed and are presumably at all times dedicated to the service of their country, but they are not eager to subject themselves to needless restrictions and even humiliations that work for the government is now believed to entail. The question is also raised regarding whose function it may be, in an atmosphere of mutual suspicion, to investigate the security officers themselves, for it is obviously illogical that such clearance should be in their own hands.

In the final analysis a free society cannot save its freedom by a complete surrendering of it, even to its own agents. Freedom, on the other hand, has never been threatened on such a mammoth scale. The greatest problem that the democratic system has to solve is that of discovering the least extent to which personal liberty must be surrendered in order that its principles may survive.

"MISGUIDED MISSILES"

UNDER the above singularly appropriate title the Travelers Insurance Companies have produced the twenty-first booklet on traffic accidents in their annual series. As usual the publication is profusely illustrated with gently humorous cartoons — humorous even when they deal with unexpected and unnecessary death and destruction.

The fact that traffic-accident statistics have shown a definite improvement over 1953 is encouraging but does not render them very much less frightening. Traffic deaths, in round figures, totaled 35,500 last year, compared with 38,500 in 1953, and injuries totaled 1,960,000, compared with 2,140,000 in the previous year. It is still a little early to say that the gains recorded are because the American driving public is acquiring conservatism, mercy and general common sense at the rate indicated.

A breakdown of the gross figures is of interest. Excessive speed remains the most virulent of the lethal agents, destroying 12,380 human organisms in 1954 compared with 13,870 in 1953. In each year approximately 659,000 injuries were the result of fast driving. As usual, free wheelers under twenty-five years of age, comprising 14 per cent of all drivers, accounted for more than 24 per cent of the fatal accidents.

Again, the Sabbath and its eve, crowding the roads with drivers of all degree, accounted for the usual week-end swelling of the grim total — these hundred-odd days produced 13,980 killed and 678,000 injured, compared with the 1953 record of 15,800 killed and 800,000 injured. Saturday, of the two, is the more dangerous day on which to go abroad, and the cotter's Saturday night is the one during which his pulseless body is most likely to be returned to his late residence.

Pedestrians have acquired either a modicum of the instinct for self-preservation or an increased agility, since deaths among these adventurers on the public way fell from 8600 in 1953 to 7700 in 1954.

The fascination of velocity untempered by any sense of the reality of impact is the producer *par excellence* of physical injury and traumatic death. Time should soon tell whether safety programs and improved highway engineering will be capable of offsetting the blinding influence of the 1955 color combinations fancied by the automotive industries.

POSTGRADUATE MEDICAL INSTITUTE

ACTUATED by the suspicion that opportunities for postgraduate medical study were in general disorganized or underorganized, overlapping, inadequate and confused, the Committee on Postgraduate Medical Education of the Massachusetts Medical Society four years ago set about the matter of a survey of the subject. The services of Mrs. Charlotte W. Troutwine were obtained for the conduct of the survey, the results and the fruits of which she has described in a recent issue of the *Journal of Medical Education*.

A collaborative grant of $5,000 was obtained for the purpose from such disparate sources as the medical schools of Harvard, Boston University and Tufts College, the Harvard School of Public Health, the Massachusetts Department of Public Health, the Massachusetts Medical Society, the Massachusetts Academy of General Practice, the Lahey Clinic, the Joslin Clinic, the American Cancer Society, Inc. (Massachusetts Division), the Arthritis and Rheumatism Foundation (Massachusetts Chapter), the Massachusetts Heart Association, Inc., the Massachusetts Tuberculosis and Health League, Inc., the National Foundation for Infantile Paralysis, Inc., the Boston Tuberculosis Association and the Charles H. Hood Dairy Foundation.

The survey, established on a temporary basis, became so effective that it seemed desirable to incorporate it on a more permanent, continuing level, and so it was done; in 1952 the Postgraduate Medical Institute was legally chartered as a nonprofit educational organization. As such it became and has continued to be a clearing house and source of information relative to postgraduate instruction in Massachusetts and New England.

The Institute, however, is more than a central agency for the diffusion of information regarding opportunities for instruction. In addition to maintaining lists of clinics, conferences and courses taking place in the hospitals and under the auspices of the medical schools of New England and keeping up to date a panel of speakers to be drawn on when occasions arise, it offers of itself courses in general medicine that are going forward in 8 different areas, some of them relatively remote from the Boston headquarters.

Most of these courses are given weekly — every two weeks in some communities — and consist mainly of two-hour sessions. The courses given in Boston average 25 and those in other areas 10 or 12 sessions. All courses sponsored by the Institute are credited by the American Academy of General Practice against the stipulated requirement for postgraduate education of a hundred and fifty hours every three years.

Although the courses in general medicine last year paid for themselves out of the very reasonable fees collected, the other services offered by the Institute are dependent on such sources as the appropriation from the Massachusetts Medical Society, the balance from those organizations already listed as original contributors, and contributions received from philanthropic and research foundations.

This is New England's Postgraduate Medical Institute today; in view of its expansion in a scant three years only an unobstructed imagination can visualize its possibilities in relation to the medical education of tomorrow.

SWEET HOURS OF EASE

THE insistence of man on postponement of the final summons to which all must respond has given rise to some interesting numerical relations, according to the perseverant statisticians of the Metropolitan Life Insurance Company. These altered statistical rates and ratios have resulted partly from the impact of modern public-health measures on human ecology in those countries that have been subjected to their influence, and partly from the social, economic and industrial progress that has been the reward and the penalty of man's restless genius.

Emphasizing two apparent effects of this genius — that man's hours of employment have become less dangerous as well as fewer in number and his hours of recreation more hazardous as well as more numerous — is the fact that American wage earners have fewer accidents while working than when otherwise engaged. Thus, according to Metropolitan Information Service, nearly 70 per cent of accidental deaths and more than half of the nonfatal disabling accidents among workers occur when they are not working.

The proportion of accidental deaths obviously varies with types of occupation. Thus, among males with industrial insurance in the Metropolitan Life Insurance Company, nonoccupational accidents accounted for the entire accident death toll in the years 1951 through 1953 in workers in textile mills, in furniture, shoe and clothing factories and among barbers. White-collar workers, interestingly enough, were not so favorably affected although fewer than one in ten of their fatalities from accidents occurred during the hours of employment. Even among workers with greater occupational hazards the free hours were more productive of fatal accidents than was the working time. Among carpenters and painters four fifths of such fatalities, among iron and steel workers three fourths, among fishermen and railroad-train crews two thirds and among chauffeurs, structural iron workers and welders more than half were sustained in unemployed time.

Emphasizing the enhanced mortality of man as compared to woman are the increased throngs of widows in the country, now numbering more than 7,400,000, or nearly double the less than 4,000,000 wearers of the weeds in 1920. Even so, the proportion of widows in the population compared to unwidowed women has decreased, as a result of the general decline in mortality of both sexes. At the ages under forty-five the proportion of widows in the female population has declined by two fifths since 1920, and at ages forty-five to fifty-four the decline has been nearly a third. About one woman in every two who now becomes widowed has still more than twenty years of life ahead, according to the Metropolitan's relentless calculators.

Treatment of Nocturnal Incontinence of Urine in Children. — *Dr. Blaschko, of Freyenwalde, asserts that he has always succeeded in this infirmity by the use of a mixture of equal parts of Tr. Nucis Vomicae and Tr. Ferri Acetici, in the dose of from 10 to 13 drops, twice each evening. In one case which resisted all treatment he resorted with success to a rotary battery; the conductor, a fine copper wire, being introduced into the meatus urinarius.*

Boston M. & S. J., *June 21, 1855*

MASSACHUSETTS MEDICAL SOCIETY

COMMITTEE ON MATERNAL WELFARE

LACERATION THROUGH THE LOWER UTERINE SEGMENT

A thirty-five-year-old gravida VII, para V, was admitted to the hospital two weeks after her calculated term. The prenatal course had been unevent-

ful except for cramps and bleeding in the fourth month. On admission the temperature was 99° F., the pulse 80, and the blood pressure 138 systolic, 70 diastolic; the red-cell count was 2,920,000, with a hemoglobin of 8.5 gm. per 100 cc. The urine gave a + test for albumin, and the sediment was loaded with white cells. Because of the anemia, 1 unit of blood was typed, crossmatched and kept in readiness. Because of a history of extremely rapid labors in the same clinic, a castor-oil and enema induction was done. Labor began shortly afterward and was of about ninety minutes' duration, but was ineffectual until the last twenty minutes, when the cervix went from 1:5-cm. to full dilation. Delivery of this clinic "service" patient, however, was not precipitate. Severe vaginal lacerations bled profusely, requiring repair. The previously prepared blood was ordered sixteen minutes after delivery but did not actually reach the patient for forty minutes; during the interval she continued to bleed furiously and, already markedly anemic, went into an irreversible state of collapse and died approximately an hour and a half post partum. Autopsy showed a laceration through the lower uterine segment.

This case was classified as a preventable death. Obviously, earlier and more copious transfusion with prompt operation might have saved the patient's life, which was lost because of a compounding of minor but lethal delays. One gets the impression that the obstetrician, who happened to be on call and was previously unacquainted with the patient, was struggling mightily against overwhelming odds with little if any assistance. The immediate availability of an additional pair of trained hands in the form of a resident or intern for just such cases is highly desirable and should perhaps be instituted in this clinic. The severe anemia, known before efforts at induction, very quickly resulted in death once hemorrhage had begun. The transfusion of a pregnant woman no longer carries the risk that it was once thought to have and is often justified in cases in which the hemoglobin is as low as this patient's was. Preoperative transfusions would, in fact, have given her a longer interval for exploration of the birth canal before the onset of irreversible shock.

JOHN FIGGIS JEWETT, M.D.
Chairman

DEATHS

KIRKENDALL — Henry Laing Kirkendall, M.D., of Worcester, died on April 24. He was in his fifty-first year.

Dr. Kirkendall received his degree from the Long Island College of Medicine in 1931. He was a former fellow of the American Medical Association. He was a member of the American Academy of Obstetrics and Gynecology, New York Academy of Sciences, New England Obstetrical Society and the Association of Military Surgeons of the United States.

He is survived by his widow, one son and three daughters.

SEELYE — Ralph Holland Seelye, M.D., of Hingham, died on May 18. He was in his ninety-first year.

Dr. Seelye received his degree from Harvard Medical School in 1889.

He was the president of the medical staff and vice-president of the board of trustees of Springfield Hospital, a fellow of the American College of Surgeons, and a member of the New England Surgical Society.

He is survived by three children, five grandchildren and four great-grandchildren.

BOSTON MEDICAL LIBRARY

JAMES FRANCIS BALLARD

1878-1955

The death of James F. Ballard, director of the Boston Medical Library and book-review editor of the *Journal*, occurred suddenly, on Sunday, May 15, as he was preparing to leave his home in Milton for the annual meeting of the Medical Library Association in Milwaukee. On the previous day he had spent his usual Saturday morning at the Library. In the afternoon he had watched a baseball game on television and in the evening had joined his group of old cronies at poker session, a game that he had enjoyed for many years.

Jim Ballard was an unusual person. He had spent sixty-three years, since the age of fourteen, in close association with the Boston Medical Library. For the last fifty years he was virtually in charge of the Library and built it up to its present level. Widely recognized in the country as the "dean" of medical librarians, he had been president of the Medical Library Association and a leader in all its activities. He will probably best be remembered for the *Boston Medical Library, Medical Classification*, first published in 1921 and finally revised in the third edition in 1946. This classification scheme was adopted by most of the libraries in the country and by some abroad. Certain of the larger libraries later turned to other systems, but it is still standard for medical libraries of small and medium size, and more than 1000 copies of the third edition were sold.

Although his primary interest was in medical librarianship, particularly in the field of certification of librarians, after adequate training in accredited schools, and in raising the standards of medical libraries throughout the world, his love for old medical books and his knowledge of them made his name known to all booksellers, collectors and doctors with antiquarian leanings both in America and Europe. He had a rare understanding of incunabula, early English imprints and indeed all books of whatever period that were of medical interest. He presumably knew more about old medical books than almost anyone living in his time.

He was a self-made man with only a month of education in the eighth grade, and yet he made himself an authority in a highly specialized field, learning to read Latin, German, French, Hebrew and,

more recently, Russian. He was meticulous in the care of the valuable material entrusted to him, although careless about his personal appearance and often a little gruff in manner. When it came to the treasures in the Library, no one could have been a finer custodian and guarded them more carefully, or handled them with more reverence. He came to symbolize the Library and ran it, of course, as a "one man show" long after it might have become more standardized in form. He was what the book world would call a "unicum," one of a kind, who set a pattern that can never be duplicated.

Mr. Ballard's life spanned a long period, and he was fond of recalling the time when he delivered books to Oliver Wendell Holmes in the last part of the nineteenth century. Harvey Cushing, William Osler, Arnold Klebs, Richard Cabot and a host of other Boston physicians knew him intimately and, indeed, were his close friends. He had the happy faculty of getting along in all walks of life and was equally at home in a bookseller's dusty warehouse in Paris or Madrid and in the more stately confines of some of the Back Bay physicians' houses. He was always a little reserved and perhaps difficult to know well, but once the bridge was crossed, no one could have a finer friend or one with more enduring qualities.

H.R.V.

BOOKS OF HISTORICAL IMPORTANCE

Historical Review of British Obstetrics and Gynaecology. Edited by J. M. Munroe Kerr, R. W. Johnstone and Miles H. Phillips. 8°, cloth, 420 pp. Edinburgh and London: E. and S. Livingstone, Limited, 1954. This volume was a gift to the Royal College of Obstetricians and Gynaecologists on the occasion of its semi-jubilee. It is written as a sequel to H. R. Spencer's *History of British Midwifery, 1650-1800.* There is an interesting chapter in which the work of Alexander Gordon (1795), Oliver Wendell Holmes (1843) and Ignaz Semmelweis (1861) on puerperal fever is noted.

Neue deutsche Biographie. Edited by the Historical Commission of the Academy of Science of Bavaria, this biographic record has begun publication with the first volume (Aachen–Behaim) at Berlin in 1953. It is not a new edition of the *Allgemeinen deutschen Biographie,* but an entirely new work. It contains the names of many physicians and scientists from the earliest times to the present.

CORRESPONDENCE

COMBINED FUND DRIVES

To the Editor: You may not be aware that here in the Middle West many physicians are regular readers of the *New England Journal of Medicine.* We regard it as one of the best medical journals published. Regularly each week I turn to and read the editorials. I am somewhat puzzled about the point of the editorial, "E Pluribus Unum," in the May 5 issue. Is it intended simply as an explanation of why the fund-for-a-disease organizations do not want to join combined fund drives, or is it a subtle way of expressing the opinion of the *Journal* that they should continue independent campaigns? If the latter, other questions need discussing — for example, the soundness of the $130,000,000 estimate. Could such an annual sum be spent wisely? Another question that frequently comes up regarding these numerous special campaigns is the overhead expense for administration and publicity and the cost of the separate fund-raising campaigns. These are important questions to those who are asked to give to these numerous special funds.

Many physicians have been quite apprehensive over the growth and publicity methods of some of these ancillary medical groups, raising such questions as the use of the funds for research. Will that cause the direction and scope of the research in medical institutions to be controlled to a large extent by outside special groups? Would this not lead to the shackling of the broad basis of research that is so essential?

The financial success of these organizations depends on their obtaining publicity for the particular disease. In this aspect the National Foundation for Infantile Paralysis surpasses all the others put together. This explains the figures quoted in the editorial although, as it points out, poliomyelitis is less important quantitatively than some of the other diseases. Many physicians believe that the publicity methods used by the Foundation have gone quite out of bounds.

I wish the *Journal* would express itself on the Ann Arbor publicity stunt, when the data on the mass vaccination study in 1954 were given unparalleled and unprecedented lay publicity before other scientists and physicians, who have the responsibility for the use of the vaccine, had the opportunity to study and evaluate the data. The *Journal of the American Medical Association* buried these data in the back of a recent issue without critical comment. I am sure that you in New England are as much concerned with the happenings of the last four weeks as physicians are throughout the rest of the country. So far the only criticism I have seen of the undue haste and the way in which the Salk vaccine was

publicized, which led the public to believe that poliomyelitis was "conquered," was, of all places, in the *Wall Street Journal*. As yet I have seen no discussion in medical journals, although physicians as individuals are most articulate. One can imagine what would happen if, for example, the American Cancer Society should announce a promising experimental cure of or vaccine for cancer in the same way for purposes of publicity. Aspects such as these, which concern the fund-for-a-disease organizations and involve the integrity and future of American medicine, are more important than the amount of money raised.

The outspoken comment of a Texas physician (as reported in a newspaper) when he first learned from a nonmedical weekly magazine that the same safety checks had not been made on the vaccine in current use as were made on the 1954 vaccine from which the conclusion of "safe" was drawn is pertinent: "That's a hell of a way for a doctor to have to get his information."

This remark raises, I believe, a basic issue of greatest importance to the medical profession. Has a lay-controlled group that financially aids medical research the moral right to present the results of the research to the public before other scientists and physicians have had the opportunity to study the data?

It would be of great interest to us here in the hinterland to have the views of the distinguished *New England Journal of Medicine* on the total picture and place of these groups. Although we recognize their altruistic purpose the deplorable mess in which the medical profession has been placed these last few weeks by the publicity methods of one of these groups calls for a calm, but thorough, discussion of their place, function and control.

BORDEN S. VEEDER, M.D.

St. Louis, Missouri

Note: The editorial, *"E Pluribus Unum,"* attempted to show why the many and increasing medical charitable organizations prefer to go it alone rather than to subject themselves to the discipline of a concerted action. The intent was not to condone their attitude, which many believe to be intrinsically self-interested. The *Journal* has more than once declared itself in favor of united drives, conservatively organized and liberated from the deplorable publicity-seeking methods that have been imposed on a number of the present independent campaigns.

The *Journal* refrained for some time from commenting on the poliomyelitis-vaccine situation because of its shifting confusion and an awareness of the fact that any comment might be quite out of date by the time it was published.—ED.

BOOK REVIEWS

A Doctor Talks to Women: What they should know about the normal functions and common disorders of the female organs. By Samuel Raynor Meaker, M.D. 8°, cloth, 231 pp., with illustrations. New York: Simon and Schuster, Incorporated, 1954. $3.95.

In this book the author, who has also published monographs entitled "Human Sterility" and "Mother and Unborn Child," accomplishes with amazing success the almost impossible project of composing a sound, sensible and reliable popular text for women about women and their reproductive systems, aiming "to assemble in one volume all the information most likely to be wanted" from their physicians by intelligent women patients about their sex organs. In easily comprehensible, nontechnical language, he covers the entire field of clinical gynecology, "from the womb to the tomb," in 29 chapters, telling his readers what a well informed woman should know about her normal functions and their common disorders, and diseases. This he does with the good sense of a good doctor, the good taste of a perfect gentleman and the good humor of both. A final chapter, "The Womb, the Woman, and the World," summarizes and evaluates the importance of the patient's personality in relation to "the world as represented by that segment of society in which each woman lives."

The text is well illustrated by a dozen well-chosen, admirable, anonymous drawings.

ROBERT M. GREEN, M.D.

Diseases of the Knee: Management in medicine and surgery. By Anthony F. DePalma, M.D., James Edward Professor of Orthopedic Surgery and head, Department of Orthopedic Surgery, Jefferson Medical College, attending orthopedic surgeon, Jefferson Medical College Hospital, Philadelphia, attending orthopedic surgeon, Methodist Episcopal Hospital, Philadelphia, chief orthopedic surgeon (rotating), Philadelphia General Hospital, consultant orthopedic surgeon, New Jersey Orthopedic Hospital, and consultant orthopedic surgeon, Veterans Administration Hospital, Philadelphia. 4°, cloth, 840 pp., with 455 illustrations (drawings by Carl Brill). Philadelphia: J. B. Lippincott Company, 1954. $20.00.

The rapid advances in all fields of medicine justify the publication of a large volume on a single articulation. This joint, the largest in the body, has been the subject of more discussion than any other, including the hip. This book offers as complete as possible a review of knowledge of the knee joint. It begins with a discussion of the comparative anatomy of the hind limb and the embryology of the knee joint. Traumatic lesions, diseases, the arthritides and neoplasms in this region are fully covered.

This carefully compiled book brings up to date properly documented and classified knowledge. Unfortunately, as soon as such a volume is published, a revision is almost immediately necessary because of new discoveries and of changing opinions. The book is well written but one occasionally tires of the indirect lengthy statements and the constant use of polysyllabic words when good old English monosyllables would seem to serve better. The drawings are excellent, as are the photographs. A carefully prepared bibliography is added to each chapter. This excellent treatise can be read with profit by orthopedic surgeons and will be of value to all who treat disabilities of the knee joint.

JOHN G. KUHNS, M.D.

BOOKS RECEIVED

The receipt of the following books is acknowledged, and this listing must be regarded as a sufficient return for the courtesy of the sender. Books that appear to be of particular interest will be reviewed as space permits. Additional information in regard to all listed books will be gladly furnished on request.

Clinical Roentgenology. Vol. 2. By Alfred A. de Lorimier, M.D., radiologist, Saint Francis Memorial Hospital, consultant in radiology for the United States Army at the Letterman Army Hospital, and consultant in radiation therapy for the United States Public Health Service at the United States Marine Hospital, San Francisco, California; Henry G. Moehring, M.D., radiologist, Duluth Clinic, Duluth, Minnesota; and John R. Hannan, M.D., radiologist, Cleveland, Ohio, radiologist, Lake County Memorial Hospital, Painesville, Ohio. 4°, cloth, 464 pp., with 734 illustrations. Springfield, Illinois: Charles C Thomas, 1954. $18.50.

This second volume of a standard set is devoted to the skull, paranasal sinuses, teeth and spine. The first volume concerned the extremities. Succeeding volumes will deal with the lungs, cardiovascular system, the digestive tract and related organs. Each volume may be purchased separately. The set should be in all collections on the subject.

Community Health Action: A study of community contrast. By Paul A. Miller, with the assistance of J. Allan Beegle, Duane L. Gibson, Charles R. Hoffer, Charles P. Loomis, Christopher Sower and David G. Steinicke. 8°, cloth, 192 pp. East Lansing, Michigan: Michigan State College Press, 1953. $3.00.

This extensive study deals with the successful efforts of 218 communities in different parts of the country in acquiring hospital facilities. The methods of achieving widespread local co-operation are discussed in detail. There is a bibliography of 10 pages and an index. The book should be in public-health collections.

Diencephalon: Autonomic and extrapyramidal functions. By Walter Rudolf Hess, M.D., professor of physiology, emeritus, University of Zürich, Switzerland. 8°, cloth, 79 pp., with 33 illustrations. New York: Grune and Stratton, 1954. $4.00. (Vol. 3, *Monographs in Biology and Medicine.)*

Professor Hess has been concerned for thirty years with the physiology of the nervous system and especially with the autonomic functions. All his articles and books have been written in German. In this small book he summarizes his findings in English for the first time. The text is divided into two parts: the functions of the diencephalon and neighboring related areas; and the integration of autonomic functions. There is a bibliography of 139 references and an index. The monograph should be in all collections on the nervous system.

Diseases of the Skin. By Oliver S. Ormsby, M.D., Rush Professor of Dermatology Emeritus, University of Illinois College of Medicine, and attending dermatologist to the Presbyterian Hospital of Chicago; and Hamilton Montgomery, M.D., M.S., professor of dermatology and syphilology, Mayo Foundation for Medical Education and Research, Graduate School, University of Minnesota, Rochester, Minnesota, and consultant, Section of Dermatology and Syphilology, Mayo Clinic. Eighth edition, thoroughly revised. 8°, cloth, 1503 pp., with 666 figures containing 750 illustrations and 18 colored illustrations on 11 plates. Philadelphia: Lea and Febiger, 1954. $22.00.

This standard textbook, first published in 1915, has been thoroughly revised, and the text brought up to date since the issuance of the last edition in 1948. Much material has been added, and the obsolete deleted. The publishing is excellent. The book is recommended for all medical libraries.

Why We Became Doctors. Edited by Noah D. Fabricant, M.D. 8°, cloth, 182 pp. New York: Grune and Stratton, 1954. $3.75.

The editor has gathered quotations from the writings, or from short sketches written for the book, of 50 physicians who became eminent in their profession or other fields of endeavor. The book is interesting and should find a place in all collections on medical and general history.

Office Gynecology. By J. P. Greenhill, M.D., F.A.C.S., F.I.C.S., attending obstetrician and gynecologist, Michael Reese Hospital, professor of gynecology, Cook County Graduate School of Medicine, attending gynecologist, Cook County Hospital, and editor, *Year Book of Obstetrics and Gynecology.* Sixth edition, revised and enlarged. 8°, cloth, 517 pp., with 127 illustrations. Chicago: Year Book Publishers, Incorporated, 1954. $7.75.

In this edition a book first published in 1939 has been thoroughly revised and in part rewritten. The publishing is excellent and there is a good index. The chapters on the control of conception place the book outside of Massachusetts statute law.

Ciba Foundation Symposium on the Kidney: Arranged jointly with the Renal Association. Edited by A. A. G. Lewis, M.D., M.R.C.P., and G. E. W. Wolstenholme, O.B.E., M.A., M.B., B. Ch., assisted by Joan Etherington. 8°, cloth, 333 pp., with 125 illustrations. Boston: Little, Brown and Company, 1954. $6.00.

This volume contains the full proceedings of the symposium on the kidney held in London in July, 1953. Thirty-five persons read papers or took part in the discussions. The text is divided into five parts; structural and functional relations; tubular functions other than the regulation of acid-base balance; renal share in the regulation of acid-base balance; general problems of electrolytic excretion; and renal share in volume control of body fluid. The authors of the various papers have surveyed the pertinent literature of their subjects, and selected lists of references are appended to the chapters. There are indexes of authors and subjects. The book is the eighth in an important series of symposiums, all excellent. The complete series should be in all medical libraries.

Lectures on the Scientific Basis of Medicine. Vol. 2. 1952-53. British Postgraduate Medical Federation, University of London. 8°, cloth, 380 pp., with illustrations. London: Athlone Press. (Distributed in the United States by John de Graff, Incorporated, New York City.) 1954. $6.00.

This second volume of an important series contains 19 articles by physicians and scientists, including 1 by Sir Alexander Fleming on recent progress in antibiotics. Extensive bibliographies are appended to the articles, and the pertinent literature is surveyed. A complete list of the lectures, which began in 1951, is appended to the text. There should be an index to the volume. The publishing is excellent. The complete series should be in all medical libraries.

Medicine for Nurses. By W. Gordon Sears, M.D. (Lond.), M.R.C.P. (Lond.), physician superintendent, Mile End Hospital, London, and examiner to the General Nursing Council for England and Wales. Sixth edition. 12°, cloth, 520 pp., with 79 illustrations. London: Edward Arnold, Limited, 1954. (Distributed in the United States by Williams and Wilkins, Baltimore.) $4.00.

This synopsis was first published in 1935 and has gone through 14 previous editions and reprintings, the last in 1952. This edition has been revised, and the material brought up to date. There is a good index, and the publishing is excellent.

Practical Fluid Therapy in Pediatrics. By Fontaine S. Hill, M.D., assistant professor of pediatrics, University of Tennessee College of Medicine, and staff member of the John Gaston Children's Hospital, Memphis. 8°, cloth, 275 pp., with 20 illustrations and 17 tables. Philadelphia: W. B. Saunders Company, 1954. $6.00.

This is a comprehensive text on its subject. The text is divided into three sections: basic physiologic principles and their clinical significance; diagnosis and treatment of clinical conditions; and technical procedures. The second part discusses solutions used in parenteral administration, and the fluid therapy of diarrhea, diabetic coma, renal disease, pyloric stenosis and nonobstructive vomiting, acute infections, salicylate poisoning, surgical conditions, burns and respiratory acidemia and alkalemia. There are lists of important source books, a bibliography, a glossary and a good index. The publishing is excellent. The book is recommended for all pediatric collections.

Donovanosis. (Granuloma Inguinale, Granuloma Venereum.) By R. V. Rajam, M.S., director, Venereal Diseases Department, Government General Hospital, Madras, and professor of venereal diseases, Madras Medical College; and P. N. Rangiah, M.D., associate professor of venereal diseases, Madras Medical College, and physician, Venereal Diseases Department, Government General Hospital, Madras. 8°, paper, 72 pp., with 24 plates and 2 tables. Geneva: World Health Organization, 1954. (*World Health Organization Monograph Series* No. 24.)

The authors discuss the etiology, epidemiology, clinical features, diagnosis and treatment of the diseases. There is a bibliography of 82 references and the text is illustrated with 24 plates.

Emergency Treatment and Management. By Thomas Flint, Jr., M.D., director, Division of Industrial Relations, Permanente Medical Group, Oakland and Richmond, California, and chief, Emergency Department, Permanente Medical Group, Kaiser Foundation Hospital, Richmond, California. 8°, cloth, 303 pp. Philadelphia: W. B. Saunders Company, 1954. $5.75.

The author discusses the emergency treatment and management of patients from the time of the first examination until disposition for definitive treatment can be arranged —

"portal-to-portal" care in emergencies. The text is divided into three parts: general principles and procedures; treatment of specific conditions (arranged alphabetically by conditions); and administrative, clerical and medicolegal procedures. There is a good index. The book should prove valuable to the practicing physician.

Retinal Circulation in Man and Animals. By I. C. Michaelson, Ph.D. (Glas.), F.R.F.P.S. (Glas.), D.O.M.S. (Eng.), adviser in ophthalmology to the Government of Israel, and chief, Department of Ophthalmology, Government Hospital, Haifa. With a foreword by Jonas S. Friedenwald, M.D., associate professor of ophthalmology, Johns Hopkins University School of Medicine. 8°, cloth, 146 pp., with 95 illustrations and 10 tables. Springfield, Illinois: Charles C Thomas, 1954. $6.75.

This study of the anatomy and physiology of the retinal blood vessels in lower animals and man seeks to throw light on the etiology of retinitis proliferans. There is a list of references and an index. The publication is excellent. The book should be in all collections on ophthalmology.

Psychology, the Nurse and the Patient. By Doris M. Odlum, M.A. (Oxon.), B.A. (Lond.), M.R.C.S., L.R.C.P., D.P.M., Dip.Ed., senior psychiatrist, Elizabeth Garrett Anderson Hospital, London, and consultant psychotherapist, West End Hospital for Nervous Diseases, London. Second edition. 12°, cloth, 168 pp. London: Nursing Mirror, Limited; New York: Philosophical Library, 1954. $4.75.

This small book, first published in 1952, has been revised to conform to the preliminary and final examinations for state-registered nurses in Great Britain. The printing was done in England. The price seems excessive for the size of the book.

The Pyramidal Tract: Its status in medicine. By A. M. Lassek, M.D., Ph.D., professor of anatomy, Boston University School of Medicine. 8°, cloth, 166 pp. Springfield, Illinois: Charles C Thomas, 1954. $4.75.

This is an important monograph in which the literature of the anatomy, histology, pathology, symptomatology and surgery of the pyramidal tract is reviewed. There are also chapters on the history from 460 B.C. to 1870 A.D., and chronologic outlines of investigations in human and subhuman experiments. There is a bibliography of 291 references and a good index. The book should be in all medical libraries and in all collections on the nervous system.

Ergebnisse der gesamten Tuberkulose-Forschung. By H. Beitske. v. 12, 8°, Bd., 488 pp. Stuttgart: George Thieme. DM 65. (Distributed by Grune and Stratton, New York City.)

This important serial contains among others articles on atelectasis and tuberculosis, asthma and tuberculosis of the lungs, internal secretions and tuberculosis, tuberculosis of the spleen and the experimental basis of BCG vaccination. The articles constitute up-to-date summaries of the latest knowledge on their subjects. Bibliographies are appended to the articles, and there are indexes of authors and subjects. The publishing is excellent. The series should be in all special collections on the subject.

The Clinical Significance of Disturbances in the Delivery of Sweat. By Marion B. Sulzberger, M.D.; and Franz Herrmann, M.D., Department of Dermatology and Syphilology, New York University Postgraduate Medical School, and Skin and Cancer Unit, University Hospital, New York University-Bellevue Medical Center. 8°, cloth, 212 pp., with 55 illustrations and 4 graphs. Springfield, Illinois: Charles C Thomas, 1954. $6.75. (Publication No. 178, *American Lecture Series.)*

This important monograph is divided into three parts on physiology, diseases and treatment. The section on diseases discusses hyperhidrosis and dyshidrosis. The coverage is extensive. The literature has been reviewed, and there is a bibliography of 242 items. There is a combined index of names and subjects.

NONCLINICAL NOTES

PROFESSOR OF SURGERY

Dr. James C. White, chief of the Neurological Service at the Massachusetts General Hospital, has been promoted to professor of surgery of the Harvard Medical School at the Hospital.

MASSACHUSETTS SCHOOL PHYSICIANS' ASSOCIATION

At the annual meeting of the Massachusetts School Physicians' Association on May 4, officers for the next year were elected as follows: president, Dr. Joseph J. Caravaglio; vice-president, Dr. James H. McCann; and secretary-treasurer, Dr. Sidney S. Listernick.

NOTICES

INTER-SOCIETY CYTOLOGY COUNCIL

The third annual meeting of the Inter-Society Cytology Council will be held at the Statler Hotel, Cleveland, Ohio, November 11 and 12.

The morning and afternoon sessions will comprise sixteen formal papers and nine round-table discussions of cytologic problems. A symposium on the subject "Problems of Early Endometrial Cancer" will be presented.

The annual banquet will be held on Friday evening, and the business meeting on Saturday at 12:30 p.m.

Additional information may be obtained from the Secretary-Treasurer, 634 North Grand Avenue, St. Louis 3, Missouri.

SOCIETY MEETINGS AND CONFERENCES

June 17–30. Consultation Clinics for Crippled Children in Massachusetts. Page 963, issue of June 2.
June 20–24. Annual Chaplains' Conference. Page 965, issue of June 2.
June 21–25. National Association for the Prevention of Tuberculosis. Page 540, issue of March 25, 1954.
July, August and September. Beth Israel Hospital Course. Page 509, issue of March 24.
July 1–4. International College of Surgeons. Page 828, issue of May 12.
July 10–16. Congress of Nobel Prize Winners. Page 510, issue of March 24.
July 11–15. Symposium on Tuberculosis. Page 509, issue of March 24.
August 28–September 2. American Congress of Physical Medicine and Rehabilitation. Page 157, issue of January 27.
August 30 and 31 and September 1. New England Health Institute. Page 1010, issue of June 9.
October 6–8. Academy of Psychosomatic Medicine. Page 509, issue of March 24.
October 22–26. American Heart Association. Scientific Session. Page 603, issue of April 7.
October 23–27. American Institute of Dental Medicine. Page 414, issue of March 10.
November 1–3. Henry Ford Hospital Symposium on Enzymes. Page 920, issue of May 26.
November 6–13. Second International Congress of Allergology. Page 157, issue of January 27.
November 11 and 12. Inter-Society Cytology Council. Notice above.
November 19–21. American Association of Blood Banks. 8th Annual Meeting. Palmer House, Chicago, Illinois.
November 29–December 2. Interim Session of the American Medical Association, Boston.

Calendar for the Week Beginning Thursday, June 23

Thursday, June 23
*8:00–8:45 a.m. Case Presentations. Joslin Clinic. Joslin Auditorium, New England Deaconess Hospital.
*8:45–9:45 a.m. Cardiac Grand Rounds. Jimmy Fund Building. Children's Medical Center, 35 Binney Street.
*9:00–10:00 a.m. Surgical Rounds. Sherman Auditorium, Beth Israel Hospital.
*9:00–10:00 a.m. Arthritis Grand Rounds. Robert Breck Brigham Hospital.
*9:00–10:00 a.m. Grand Rounds. Russell Room, House of Good Samaritan.
*10:00–11:00 a.m. Combined Medical-Surgical Rounds. Sherman Auditorium, Beth Israel Hospital.
10:30–11:15 a.m. Lecture on Diabetes for Doctors and Patients by a Member of the Joslin Clinic. Joslin Auditorium, New England Deaconess Hospital.
*11:00 a.m.–12:00 m. Thoracic Conference. The Management of Surgical Lesions of the Aorta. Dr. Herbert D. Adams. Main Amphitheater, Peter Bent Brigham Hospital.
*11:00 a.m.–12:00 m. Pediatric Conference, Mount Auburn Hospital, Cambridge.
*11:00 a.m.–12:00 m. Medical Staff Conference. Sherman Auditorium, Beth Israel Hospital.

(Concluded on page xxxiii)